



The Accuracy of Diagnostic High Frequency Ultrasound Imaging For Musculoskeletal Soft Tissue Pathology

Authors

Dr Pooja Shamsukha^{1*}, Dr Prasanna Mishrikotkar²

¹Resident, ²Professor, Department of Radiology, MGM Medical College Aurangabad (MS) India

*Corresponding Author

Dr Pooja Shamsukha

Resident, Department of Radiology, MGM Medical College Aurangabad (MS) India

Abstract

Introduction: *With increased incidence of sports injuries the practice of musculoskeletal ultrasound is gaining wide popularity outside the traditional radiology practice. Use of musculoskeletal ultrasound other than for sports injuries includes evaluation of musculoskeletal soft tissue pathologies. Ultrasonography is a non-invasive, readily available, safe, low cost and a patient comfortable modality. Application of high resolution USG in soft tissue pathologies of musculoskeletal system has evolved exponentially in the past two decades and is useful in not only evaluating the nature of soft tissue swellings but also aids in detection of histology in mostly all cases. We undertook this study to analyze the accuracy of USG in diagnosing soft tissue musculoskeletal pathologies.*

Materials and Methods: *This was a prospective study conducted in the Department of Radiodiagnosis of a tertiary care medical college situated in an urban area. 200 subjects with superficial soft tissue swellings referred from various clinical departments were included in this study on the basis of a predefined inclusion and exclusion criteria. All the soft tissue swellings were imaged by with high resolution USG transducer of 4-12 MHz with Seimens Acuson NX3 and Phillips Affinity -30. The sonographic indices of the soft tissue swellings noted were location/plane, nature, size, margin, echo pattern and calcification. Vascularity of the lesions was assessed with color and spectral Doppler parameters. The ultrasonographic diagnosis was then correlated initially on the clinical diagnosis. Soft tissue swellings like foreign bodies, liquefied abscess and hematomas were 19 readily confirmed to evaluate the accuracy of USG in these lesions. In patients who underwent surgical excision a correlation of USG and HPE was also done. For statistical purposes p value less than 0.05 was taken as statistically significant.*

Results: *Out of total 200 patients there were 92 males and 108 females with a M:F ratio of 1:1.17. The mean age of the studied cases was found to be 33.31 +/- 16.44. Majority of the patients (55.5%) presented as painless swelling while painful swelling and traumatic swelling was seen in 54 (27%) and 35 (17.5%) patients respectively. Common locations were upper limb (33%) followed by lower limb (27.5%). Majority of the lesion were subcutaneous (60.5%) followed by arising from deeper structures (13%). On ultrasound 113 (62.5%) patients had solid lesions whereas cystic and mixed echogenic lesions were seen in 61 (30.5%) and 24 (12%) patients. In majority of the cases the lesions had a well-defined margin (63%) whereas ill-defined and lobulated margins were seen in 67 (33.5%) and 5 (2.5%) patients respectively. Most lesions were either hypoechoic (41.5%) or anechoic (24%) and on Doppler majority of the lesions were avascular (73.5%). 82*

(41%) patients had tumoral lesions whereas 108 (54%) were found to have on tumoral lesions. 20 (10%) patients had foreign body as the cause of swelling and all of them were readily diagnosed on ultrasound. Most common site of lipoma was found to be torso (26/44) and majority of them were found in subcutaneous plane (77%). Lipoma, nerve sheath tumors and ganglion cysts were found to be hyperechoic (75%), hypoechoic (66.66%) and anechoic (75%) in majority of the cases.

Conclusion: High frequency ultrasound imaging is found to be capable of diagnosing musculoskeletal soft tissue pathologies with high accuracy. It has the distinct advantage of being dynamic, non-invasive, affordable, accurate, quick and accessible imaging modality for a variety of musculoskeletal soft tissue pathologies.

Keywords: soft tissue pathologies, high frequency ultrasound, Dynamic Imaging, Echogenicity.

Introduction

Ultrasonography is a non-invasive, readily available, safe and affordable a modality. Imaging of soft tissue swellings is getting more frequent as clinicians increasingly require good quality diagnostic information in order to determine clinical and surgical management¹. Soft tissue lesions have a wide range of appearances and presentations. Though it is difficult to optimally assess all masses on Ultrasonography, its dynamic imaging, portability, patient friendly, cost-effective combined with its freedom to examine the lesion in any direction, makes it the investigation of choice as the first line modality for imaging of superficially located masses². Vascularity of the mass lesion should always be assessed with the help of Color Doppler which is of greater significance in order to prevent surgical complications. USG helps in providing characterization of solid, cystic and mixed lesions, their sizes, margins, volume, relation with surrounding structures and compartmental localization of the mass lesion³. Application of high resolution ultrasound in soft tissue pathologies of musculoskeletal system has evolved exponentially in the past two decades and is useful in not only evaluating the nature of soft tissue swellings but also aids in detection of histology in mostly all cases⁴. Apart from providing the nature and characteristics of swelling, ultrasound helps the surgeon for appropriate surgical management with least complications. Recent development in technology had the greatest impact on the use of high frequency ultrasonography for soft tissue pathologies in musculoskeletal imaging⁵.

Structures which previously thought to be unapproachable are now scanned effortlessly and evaluated accurately using high frequency probes. Although MRI is the golden imaging modality but there are problems of affordability and suitability of patients for MRI⁶.

Among the varied benefits of USG, are the ability to perform a real time study in order to assess dynamic property alongside showing the action of the structure under evaluation with added advantage to see and explore it in multiple planes for example in transverse, longitudinal and axial sections. USG is portable, more easily available and cheaper than MRI. USG machines are easily accessible and come with added benefit of repeated follow up scan without spending much time⁷. The major drawback with ultrasound evaluation of the soft tissue pathologies is its highly operator-dependent nature and hence there are always chances of interobserver differences⁸.

A profound knowledge of anatomy of musculoskeletal system is absolutely essential. One of the major advantages that MSK ultrasound has over MRI in the evaluation of tendons and nerves, is the availability of high-frequency linear probes, which allows evaluation of each and every individual fibril⁹. Added to this, is the ease, multiple repetition, comparison with opposite side and speed with which an examination can be completed. So it can be said that not one but multiple factors make musculoskeletal USG a very effective addition to the field of radiology. It has now become the technique of choice in patients with metallic implants and is also the preferred choice of imaging modality in pediatric population, where anesthesia, sedation, and

radiation are considered as major issues with other imaging modalities¹⁰. The purpose of this study was to discuss the varied presenting features of superficial soft tissue swellings on USG and its comparison with histopathological results as in when necessary.

Materials and Methods

This was a prospective study conducted in the Department of Radiodiagnosis, MGM Medical College Aurangabad, India, on 200 subjects with superficial soft tissue swellings referred from various clinical departments. Patients were included in this study on the basis of a predefined inclusion and exclusion criteria. The sample size was provided by statistical analysis of existing data of prior referrals to the department. Ethical committee approval was obtained prior to the study. Verbal and written consent was acquired from all the patients undergoing this study in their native language. Study was conducted for a period of two years from November 2016 to November 2018. All the soft tissue swellings were imaged by with high resolution USG transducer of 4-12 MHz with Seimens Acuson NX3 and Phillips Affinity-30. Patients were made to sit or lie down in supine or prone position depending on the location of the soft tissue swelling. The sonographic indices of the soft tissue swellings noted were location/plane, nature, size, margin, echo pattern and calcification. Vascularity of the lesions was assessed with color and spectral Doppler parameters. Maneuvers such as panoramic views were obtained for large lesions for better assessment. The low frequency curvilinear transducer was also used in some swellings of superficial origin showing deeper extensions. The ultrasonographic diagnosis was then correlated initially on the clinical diagnosis. Soft tissue swellings like foreign bodies, liquefied abscess and haematomas were readily confirmed to evaluate the accuracy of USG in these lesions. All patients with non-inflammatory soft tissue swellings underwent histopathological examination either by biopsy or fine needle

aspiration cytology and if needed were further treated with surgical excision. Patients with inflammatory soft tissue swellings were subjected to surgery. Probable diagnosis obtained by USG was then correlated with histopathology as and when necessary. SSPE 21 software was used for statistical analysis. P value less than 0.05 was taken as statistically significant.

Ultrasound Technique

The technique for image acquisition varies with the depth of the abnormality. Superficial masses were examined with a high-frequency (12–4 MHz) linear transducer because of its high spatial resolution. Only light pressure should be applied to avoid compressing small vessels and missing flow. We used a copious amount of gel rather than a standoff pad because the pad can be cumbersome and limit some dynamic maneuvers. For deeper masses we used lower frequency (6-2 MHz) curved-array transducers because of their better penetration and larger FOV. Whenever required more pressure was applied to the transducer for decreasing the distance between the mass and the probe, improving image quality. Orthogonal static images were used to determine the size, extent, morphologic features, and vascularity of a mass. Split-screen or extended FOV functions were used to visualize the extent of masses occupying large anatomic segments. Use of cine loops was done for complete evaluation of large masses and for obtaining extended FOV images. Both extended FOV images and cine clips were used for determining the anatomic origin of a mass. Doppler ultrasound was used in all the cases for evaluation of vascularity of the lesions. Suspected flow was confirmed with spectral analysis to avoid mischaracterizing transducer motion and twinkle artifact as flow. FNAC or biopsy was done whenever required.

A) Inclusion Criteria

1. Patient referred for imaging of superficial soft tissue swellings.
2. Those who had given informed consent to be part of study.

B) Exclusion Criteria

1. Those patients who refused consent.
2. Patients with thyroid and breast swellings.

Results

In this study of 200 patients with soft tissue swellings there were 92 (46%) males and 108 (54%) females with a M:F ratio of 1:1.17.

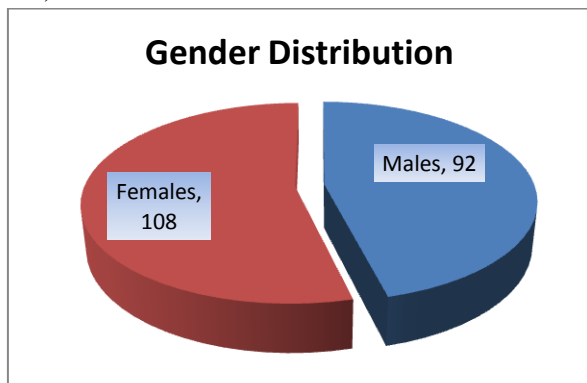


Figure 1: Gender Distribution of the studied cases.

The most common affected age group was found to be 21-30 years (31%) followed by 31-40 years (24.5%) and 41-50 years (11%). The least common affected age group was found to be less than 1 year (1.5%) and more than 70 years of age (1%). Maximum number of soft tissue swellings was obtained in the third decade of life followed by fourth decade and minimum number of soft tissue swellings was obtained in eighth decade. In this prospective study 100 subjects were enrolled, out of which 59 were females and 41 were males. Subjects of varied aged group were included in this study ranging from birth to 72-years of age with a mean of 33.31+/- 16.44 years.

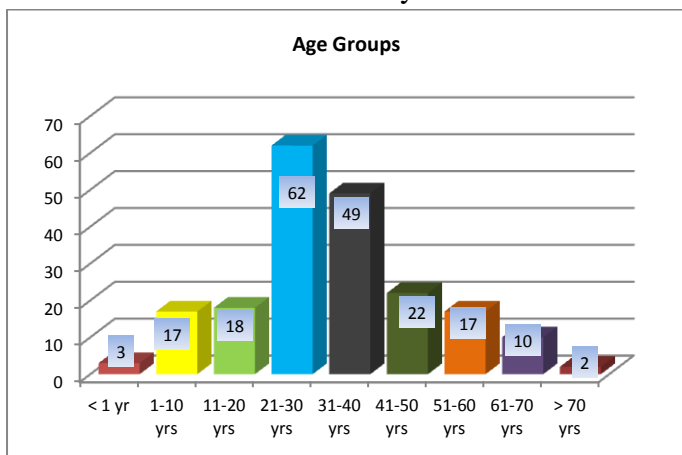


Figure 2: Age groups of the studied cases

The most common etiology was painless swelling seen in 111 (55.5%) of our patients. The next most common symptom was found to be painful swelling which was seen in 54 (27%) of our patients. Trauma was the etiological factor in remaining 35 (17.5%) cases. In general painless swellings were found to be the most common presenting complaint in the studied cases.

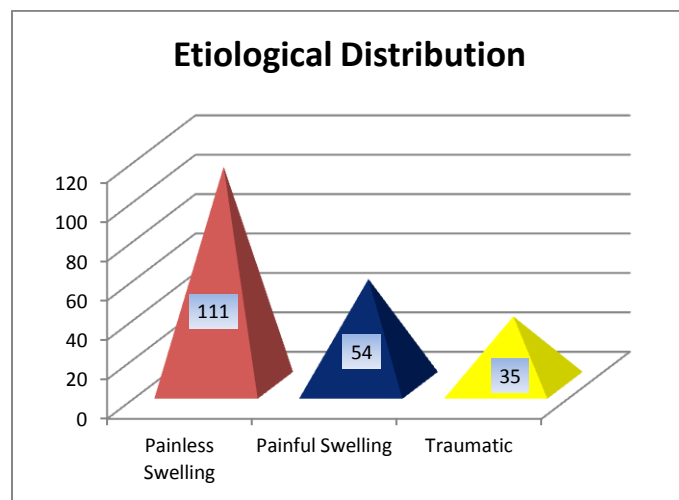


Figure 3: Etiological Distribution of the studied cases

The analysis of the anatomical site of the lesion showed that the most common site was upper limb which was involved in 66 (33%) patients followed by lower limb (27.5%) and back (13%). Other sites were involved in remaining 26.5% cases.

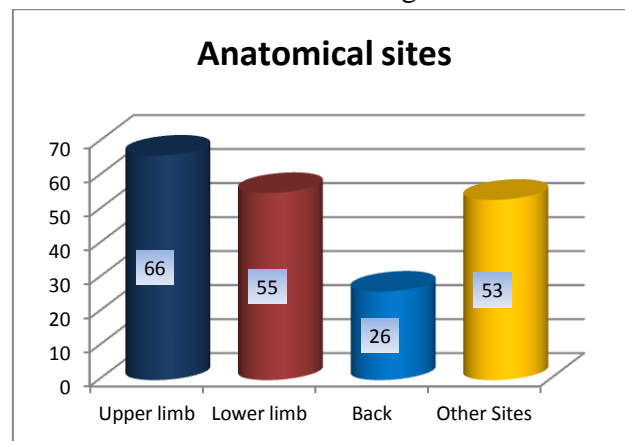


Figure 4: Anatomical Sites of lesions

The analysis of musculoskeletal pathologies according to the anatomical structures involved showed that only subcutaneous plane was involved in 121 cases (60.5%), only skin was involved in 3 cases (1.5%), only muscle in 8 (4%)

cases, while only nerve was involved in 24 (12%) cases, only tendon was involved in 21 (10.5%) cases and deeper structures were found to be involved in 26 (13%) cases. On distributing soft tissue swellings according to the anatomical plane of origin, maximum number of cases was observed in the subcutaneous plane (60.5%).

Table 1: Distribution of patients according to anatomical origin of swellings

Anatomical Origin	No Of Patients	Percentage
Subcutaneous	121	60.5%
Muscle	08	4%
Nerve	24	12%
Tendon	21	10.5%
Deeper Structure	26	13%
Total	200	100%

The distribution of the lesions on the basis of whether they were solid, cystic or mixed lesions showed that majority of the lesions were solid lesions accounting for 113 cases (56.5%) followed by cystic (30.5%) and mixed lesions (13%). The analysis of soft tissue musculoskeletal pathologies according to the margins of swelling was also done. Depending on the margins of the swelling, the lesions were classified into well defined, poorly defined, and lobulated and spiculated. In our study majority of lesions were found to have well defined margins (63%) followed by poorly defined margins (33.5%). Only 7 (3.5%) lesions had lobulated margins. There was no lesion with speculated margins. Distribution of patients was done on the basis of the echo pattern of the swellings and they were divided into anechoic, hypoechoic, isoechoic, hyperechoic and heteroechoic. In our study majority of lesions were hypoechoic (41.5%) followed by Anechoic (24), heteroechoic (18%), hyperechoic (14.5%) and isoechoic (2%) lesions. On distributing soft tissue swellings according to their echopattern maximum number of cases were observed to appear hypoechoic. On color Doppler the lesions were divided into nonvascular, minimally vascular, profoundly vascular and peripherally vascular lesions. Most of the lesions were avascular (73.5%), minimally vascular

(11.5%), profoundly vascular (7.5%) and peripherally vascular (2.5%).

Table 2: Nature, Margins, Echo pattern and vascularity of the lesions

Characteristics		No Of Patients	Percentage
Nature Of Swelling	Solid	113	55.5%
	Cystic	61	30.5 %
	Mixed	26	13%
	Total	200	100%
Margins Of Lesions	Well defined	126	63 %
	Poorly Defined	67	33.5 %
	Lobulated	07	3.5 %
	Speculated	00	00 %
	Total	200	100%
Echo Pattern	Anechoic	48	24%
	Heteroechoic	36	18%
	Hypoechoic	83	41.5%
	Isoechoic	04	2%
	Hyperechoic	29	14.5%
	Total	200	100%
Vascularity	Avascular	147	73.5%
	Mild Vascularity	23	11.5%
	Moderate Vascularity	15	7.5%
	Peripheral Vascularity	5	2.5%
	Total	200	100%

Another way of classifying soft tissue swellings was dividing them in between tumoral and non tumoral lesions. Non tumoral swellings had upper hand in the current study comprising of 108 (54%) of cases, where as tumoral soft tissue swellings were seen in 92 (46%) in number. Non Tumoral soft tissue swellings were sub classified as cystic, post traumatic and reactive/inflammatory. Reactive/inflammatory soft tissue swellings stood the majority, followed by cystic and post traumatic swellings.

Table 3: Distribution of patients according to tumoral/non tumoral swellings

Lesions	No Of Patients	Percentage
Tumoral	92	46 %
Non Tumoral	108	54 %

Among the non tumoral soft tissue swellings, the most important one was foreign bodies in soft tissues with its complications. Maximum cases of soft tissue foreign bodies had granuloma/abscess formation and majority of them were located in the upper limb. All 20 foreign bodies were echogenic with variable shadowing and were readily detected on USG.

Table 4: Type and associated complications of the cases with foreign bodies

Foreign Body		No Of Patients	Percentage
Type	Wooden	17	85%
	Plastic	2	10%
	Metal	1	5%
	Total	20	100%
Complications	Present	16	80%
	Absent	4	20%
	Total	20	100%

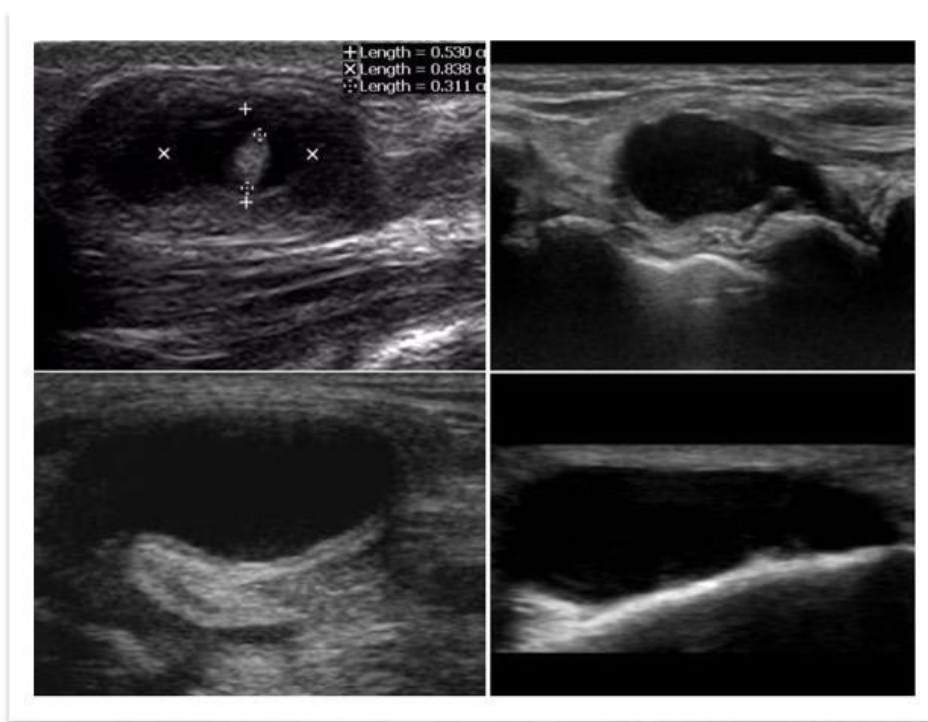

Figure 5: Images showing (Clockwise from left upper corner) foreign body, Ganglion cyst, Bakers cyst and hematoma.

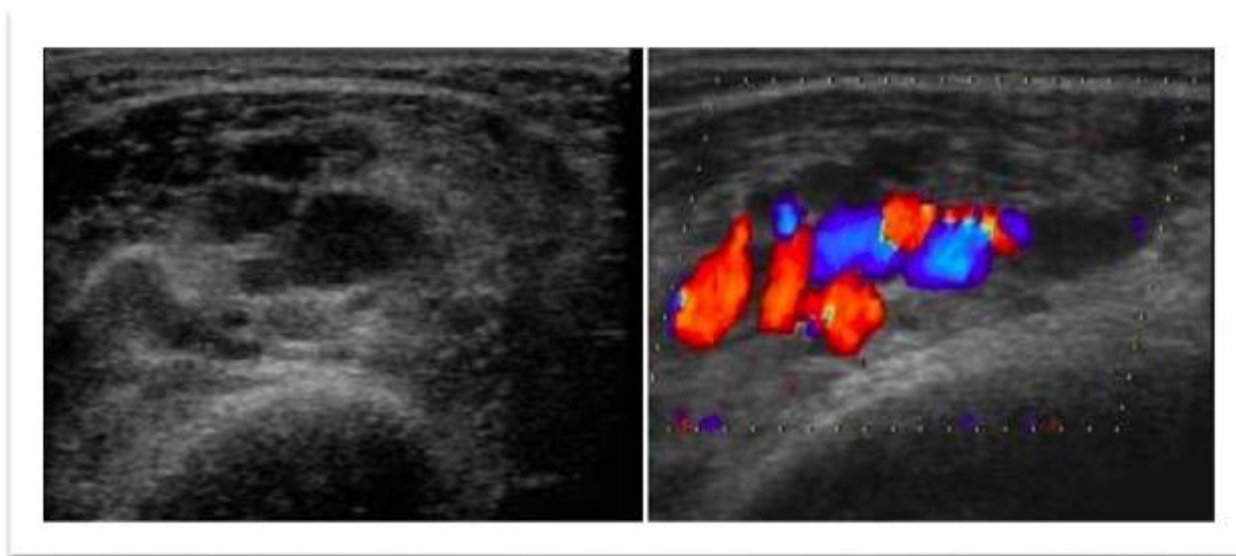


Figure 6: Subcutaneous plane of chest wall shows ill-defined heteroechoic ill-defined lesion ,on color doppler show moderate vascularity s/o slow flow vascular malformation / hemangioma

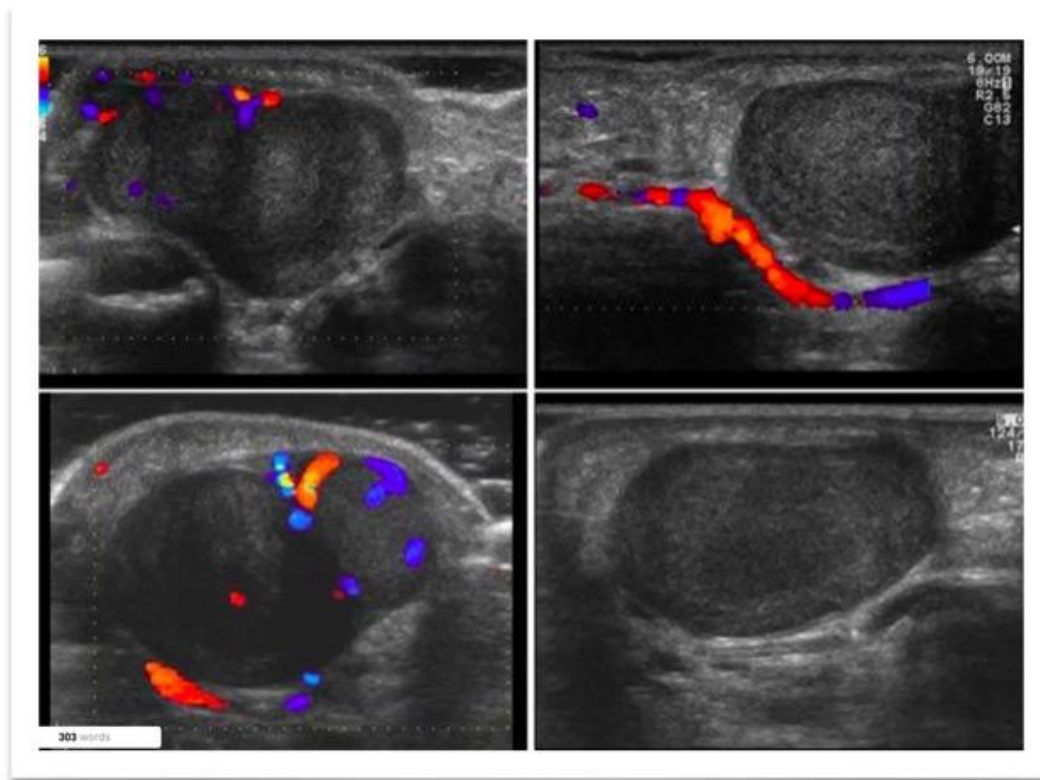


Figure 7: A well-defined hypoechoic lesion noted in subcutaneous plane along middle finger and shows significant vascularity on Doppler s/o granuloma/ benign fibrous histiocytoma.

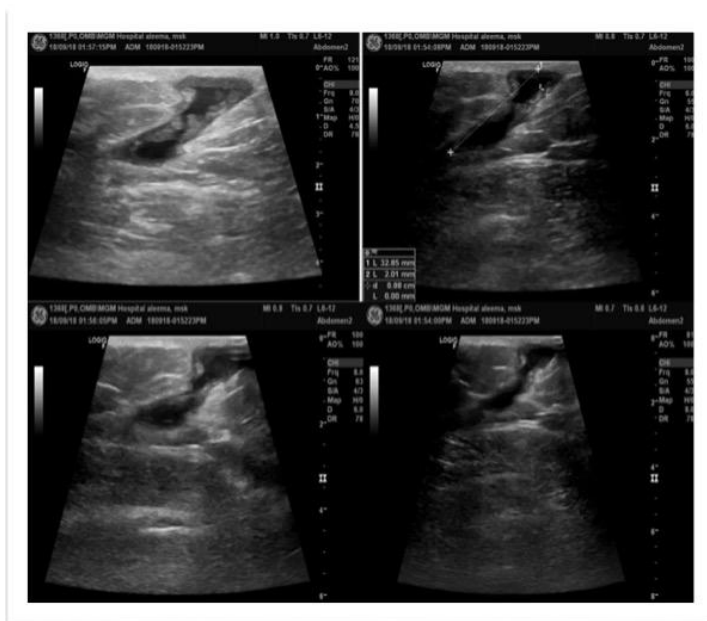


Figure 8: Linear well-defined collection in intramuscular plane extending to subcutaneous plane and showing moving internal echoes s/o abscess.

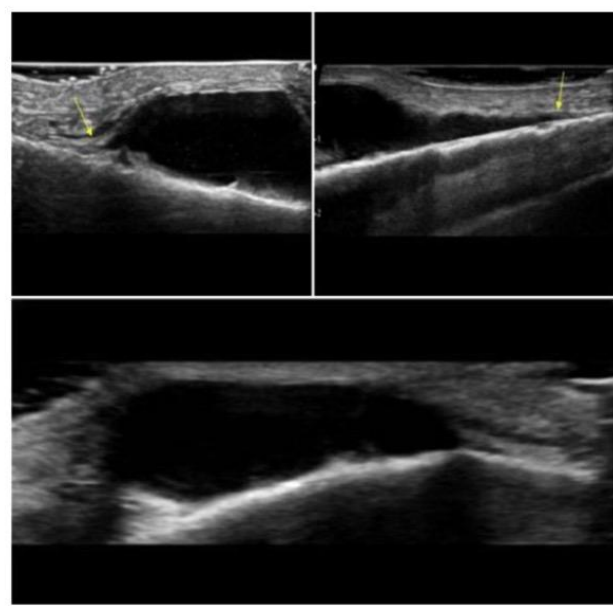


Figure 9: Heteroechoic collection at intermuscular plane showing multiple internal echoes within it, it is located along anterolateral aspect of left knee. Underlying bone appears normal overall f/s/o Hematoma/abscess.

Out of 200 cases lipoma was seen in 44 (22%) patients. The most common location of lipoma was found to be torso (59.09%) followed by upper

(36.36%) and lower limbs (4.55%).majority of these lipomas (77.27%) were found to be originating from subcutaneous plane whereas in 10 (22.73%) patients they were seen to have intramuscular origin. The predominant echo pattern was found to be hyperechogenicity which was seen in 33 (75%) cases. In 10 (22.73%) patients lesions appear hypoechoic and in only 1 (2.27%) the lesion was found to be Isoechoic.

Table 5: Location, complications and echopattern of Lipoma in studied cases

Lipoma		No Of Patients	Percentage
Location	Upper Limb	16	36.36%
	Lower Limb	2	4.55%
	Torso	26	59.09%
	Total	44	100.00%
Complications	Subcutaneous plane	34	77.27%
	Intramuscular	10	22.73%
	Total	44	100.00%
Echogenicity	Hyperechoic	33	75.00%
	Hypoechoic	10	22.73%
	Isoechoic	1	2.27%
	Total	44	100.00%

The analysis of nerve sheath tumors on the basis of echogenicity showed that out of 6 patients with nerve sheath tumors 4 (66.67%) appeared hypoechoic on ultrasound whereas remaining 2 (33.33%) appeared hyperechoic on ultrasound.

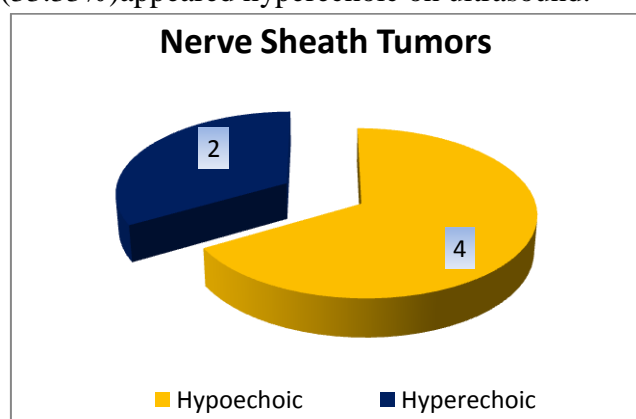


Figure 10: Echogenicity of nerve sheath tumor.

Out of 200 cases Nerve sheath tumors were present in 24 (12%) patients. Majority of nerve sheath tumors appeared Anechoic (75%) on ultrasound. In 6 (25%) patients nerve sheath tumors appeared hypoechoic. Uniloculated type was seen in 21 (87.50%) cases whereas

multiloculated nerve sheath tumors were seen in remaining 3 (12.50%) cases.

Table 11: Characteristics of Ganglion cysts in the studied cases

Ganglion Cyst	No Of Patients	Percentage	
Echogenicity	Anechoic	18	75.00%
	Hypoechoic	6	25.00%
	Total	24	100.00%
Loculations	Uniloculated	21	87.50%
	Multiloculated	3	12.50%
	Total	24	100.00%

Discussion

Superficial soft tissue swellings comprise a wide spectrum of lesions which can be primarily classified into various types based on their origin, histological type, USG features and anatomical location. In the recent past, the ability of USG to assess and diagnose a superficial soft tissue swelling has greatly increased and as technology has advanced by leaps and bounds and so is the knowledge and confidence of radiologists to ascertain a narrow differential diagnosis¹¹. USG has always been a preferred modality due to its low cost, non- invasive nature, ready availability, safety, no risk of radiation, faster reporting and a comfortable modality which has high specificity and predictive value to diagnose superficial soft tissue swellings. It won't be erroneous to infer that USG is almost equivalent to the pathological diagnosis especially in non tumoral superficial soft tissue swellings¹².

In this prospective study 200 subjects were enrolled, out of which 108 were females and 92 were males. Subjects of varied aged group were included in this study ranging from neonates to 82-years of age with a mean of 34 years. Various retrospective studies done by different authors have also showed similar variations in the age groups in soft tissue swellings. Hung E et al conducted a retrospective study in Hong Kong on 247 soft tissue tumors and in this study the affected age groups varied from 1-96 years. Another retrospective study performed by Hong-Jen Chiou et al on superficial soft tissue masses in Taipei enrolled patients with age group from 1 to 104 years¹³.

Based on the present study and with comparison with previous studies conducted by Hong-Jen Chiou et al and Hung E et al the most common site of presentation of superficial soft tissue swelling was the upper limb. In our study also the most common site of superficial swelling was found to be upper limb. The most common swelling was lipoma^{13,14}.

Amended version of WHO classification of tumors of soft tissues and bone was published in 2013¹⁵. This classification helps to classify and understand pathogenesis, histological and genetic findings of tumors. In the current study out of 200, 62 soft tissue tumors were found to have adipocytes predominated features. In the current study, the main parameters about the swelling recorded were its plane, nature, margins, echopattern, vascularity and presence or absence of calcification.

It is a combination of all parameters rather a specific single parameter which led to diagnosis in majority of the cases. The diagnosis was based upon factors such as clinical history, demographics and ultrasound parameters such as echogenicity, margins, vascularity and loculations. Hong-Jen Chiou et al in his study opined that there was no significant difference between the malignant and benign soft tissue tumors based on USG and Doppler parameters¹³. Hung E et al had a different conclusion and stated that sensitivity of differentiation between benign and malignant tumors on USG parameters is pretty high [14]. No previous study has interpreted the specificity of USG parameters in the diagnosis of non tumoral lesions. In our study we found that USG and Doppler parameters alone are not adequate to make a specific diagnosis of superficial soft tissue tumors. Lipoma was the most common benign tumor encountered as soft tissue masses. These tumors often were found to be located in the subcutaneous plane, though there locations in intramuscular and intermuscular planes aren't infrequent. On USG, most of the lipomas were found to be homogenously hyperechoic relative to the surrounding structures. Peculiar pattern of

echogenic parallel lines was also depicted by these tumors. However, some of the lipomas may be hypoechoic or even isoechoic to the surrounding structures. We may infer that lipomas have an echogenic pattern ranging from hyperechoic to hypoechoic with parallel echogenic lines being a characteristic feature. Similar ultrasound features of lipoma were reported by the authors such as Rahmani G et al¹⁶ and Ahuja AT et al¹⁷.

Neurofibromas and schwannomas are the two most common neural tumors presenting as soft tissue swellings. Both the tumors are heterogeneous and predominantly hypoechoic. Current study comprised of six nerve sheath tumors among which 5 were diagnosed on USG and one was discordant. Among the 5 tumors diagnosed on USG, 4 originated from ulnar nerve and one from the median nerve. Out of the five, two tumors were heterogeneously hyper echoic and three were hypoechoic. The discordant mass lesion was also hypoechoic on USG. Reynolds DL Jr et al in a prospective study found similar results and concluded that Peripheral nerve sheath tumors are often hypoechoic with posterior acoustic enhancement and features such as presence of intrinsic blood flow and peripheral nerve continuity are the features which points towards the diagnosis of nerve sheath tumors¹⁸.

Non tumoral swellings predominated in the current study costing for 76% of the cases. These non tumoral swellings were sub classified into cystic (27.6 %), post traumatic (13.15 %) and inflammatory or reactive (59.2 %). In our study 20 cases of soft tissue foreign body with granuloma/abscess formation were. All the 20 cases were confidently diagnosed on USG with sensitivity of 100%. Foreign bodies seen as linear or punctate echogenic lesions with variable acoustic shadowing surrounded by hypoechoic granulation tissue or abscess formation A study conducted in a rural Indian center by Saboo S et al on 123 patients showed similar high sensitivity corresponding to 94.5%. Majority of the composition of the foreign body was wood in the current study followed by metal pieces. Even in

the study conducted by Saboo S et al 82% of foreign bodies were wooden in nature and 99% were in the extremities. With reference to the above study we can conclude that foreign bodies are usually identified as hyperechoic structure with variable acoustic shadowing with surrounding hypoechogenicity suggestive of abscess or granuloma^[19].

Ganglion is a cystic mass lesion and may present as unilocular or multilocular cystic lesion with myxoid matrix. In present study the predominant echo pattern of ganglion cysts was found to be anechoic. A prospective study was conducted by George Wang et al on 20 wrist ganglia showed similar results and majority of the lesions in the study conducted by George Wang et al were found to be anechoic²⁰.

Conclusion

USG is capable of fairly reliably diagnosing superficial soft tissue swellings but no single parameter is sufficient enough to specify USG diagnosis. USG has the advantage of being patient friendly, radiation free, dynamic, quick, affordable and fairly reliable imaging modality for the diagnosis of soft tissue swellings. In many cases it may be helpful for interventions.

Bibliography

1. Campbell. In: Allan, Baxter, Weston, (editors). Clinical Ultrasound. 3rd ed. Churchill Livingstone; 2011. Pp. 1109-1125.
2. Kinare A, Brahmalkar M, D'Costa S. Ultrasound of musculoskeletal soft tissue masses. Indian J Radiol Imaging. 2007;17(3):201-08.
3. Cheng J, Tang S, Yang Y, Chou S, Wong A, Tsai W, et al. Sonographic features of soft tissue tumors in the hand and forearm. Chang Gung Med J. 2007;30:54754.
4. Chiou H, Chou Y, Chiou S, Wang H. High-resolution USG in superficial soft tissue tumors. J Med Ultrasound. 2007;15:152-74.
5. Cook CR. Ultrasound Imaging of the Musculoskeletal System. Vet Clin North Am Small Anim Pract. 2016 May;46(3):355-71.
6. Dill T. Contraindications to magnetic resonance imaging: non-invasive imaging. Heart. 2008 Jul;94(7):943-8.
7. Lento PH, Primack S. Advances and utility of diagnostic ultrasound in musculoskeletal medicine. Curr Rev Musculoskelet Med. 2007;1(1):24-31.
8. Lento PH, Primack S. Advances and utility of diagnostic ultrasound in musculoskeletal medicine. Curr Rev Musculoskelet Med. 2007;1(1):24-31.
9. Wang MY, Wang XB, Sun XH, Liu FL, Huang SC. Diagnostic value of high-frequency ultrasound and magnetic resonance imaging in early rheumatoid arthritis. Exp Ther Med. 2016;12(5):3035-3040.
10. Grover VP, Tognarelli JM, Crossey MM, Cox IJ, Taylor-Robinson SD, McPhail MJ. Magnetic Resonance Imaging: Principles and Techniques: Lessons for Clinicians. J Clin Exp Hepatol. 2015;5(3):246-55.
11. Henderson RE, Walker BF, Young KJ. The accuracy of diagnostic ultrasound imaging for musculoskeletal soft tissue pathology of the extremities: a comprehensive review of the literature. Chiropr Man Therap. 2015;23:31. Published 2015 Nov 5.
12. Jacobson JA. Seminars in musculoskeletal radiology: 2005. New York: Copyright© 2005 by Thieme Medical Publishers, Inc; 2005. Musculoskeletal ultrasound and MRI: which do I choose? pp. 135-149.
13. Hong Jen, Chiou H, Chou H, Chiu S, Wang H, Chen W, Chen T, et al. Differentiation of benign and malignant superficial soft-tissue masses using grayscale and colour Doppler USG. J Chin Med Assoc. 2009;72:307-15.

14. Hung E, James Francis Griffith1 Alex Wing Hung Ng1 Ryan Ka Lok Lee1 Domily Ting Yi Lau1 Jason Chi Shun Leung; Ultrasound of Musculoskeletal Soft-Tissue Tumors Superficial to the Investing Fascia; AJR:202, June 2014.
15. Jo VY, Fletcher CD. WHO classification of soft tissue tumors: an update based on the 2013 4th edition. Pathology. 2014;46(2):95-104.
16. Rahmani G, McCarthy P, Bergin D. The diagnostic accuracy of ultrasonography for soft tissue lipomas: a systematic review. Acta Radiol Open. 2017;6(6): 2058460117716704. Published 2017 Jun 30. doi:10.1177/2058460117716704
17. Ahuja AT, King AD, Kew J, King W, Metreweli C. Head and neck lipomas:sonographic appearance. AJNR Am J Neuroradiol. 1998 Mar;19(3):505-8.
18. Reynolds JH, Wolinski AP. Sonographic appearance of branchial cysts. Clin Radiol 1993;48:109–10. 24. Simonovsky V. Peripheral nerve schwannoma preoperatively diagnosed by sonography: report of three cases and discussion. Eur J Radiol 1997;25:47–51.
19. Saboo S, Soni S, Adhane V. High-resolution sonography is effective in detection of soft tissue foreign bodies: experience from a rural Indian center. J Ultrasound Med. 2009;28(9):1245-49.
20. Wang G, Jacobson JA, Feng FY, Girish G, Caoili EM, Brandon C. Sonography of wrist ganglion cysts: variable and noncystic appearances. J Ultrasound Med. 2007 Oct;26(10):1323-8; quiz 1330-1.