



## Squamous Cell Carcinoma (SCC) of hand in a patient of generalized vitiligo treated by surface mould brachytherapy

Authors

**Dr Seema Goel<sup>1</sup>, Dr Rajinder Kumar<sup>2</sup>**

<sup>1</sup>Assistant Professor, Department of Dermatovenereology Government Medical College, Patiala, Punjab

<sup>2</sup>General Surgeon, Department of Surgery, Mata Kaushalya Hospital

Corresponding Author

**Dr Seema Goel**

Assistant Professor, Department of Dermatovenereology, Government Medical College, Patiala, Punjab

Email: [seemapatiala@yahoo.co.in](mailto:seemapatiala@yahoo.co.in), 9814610676

### Abstract

*Non melanoma skin cancers (NMSC) are the most common malignant tumors in humans, with Squamous cell carcinoma(SCC) constituting about one-fourth of these cases. Considering that patients with vitiligo have no protective pigment (melanin) in sun-exposed depigmented skin, it would be expected that these patients develop a higher risk for photodamage and NMSC. However, there is a paucity of reports of NMSC in sun exposed, long standing vitiliginous skin as NMSC are rare occurrences in such patients. Currently, ablative surgery is almost always recommended as the treatment for most SCCs. Nonetheless, High dose rate (HDR) surface mould brachytherapy is a safe and simple alternative to surgery, in selected cases, as it successfully eradicates the tumor and also preserves hand function. We report a case of generalized vitiligo with cutaneous SCC of the hand treated with surface mould brachytherapy.*

**Keywords:** *Squamous cell carcinoma (SCC), long standing vitiliginous skin, High dose rate (HDR) surface mould brachytherapy.*

### Introduction

Non melanoma skin cancers (NMSC) are the most frequent malignant tumors in humans constituting 95% of total skin cancers, with histology revealing Squamous cell carcinoma (SCC) in 25 % of cases. Most relevant risk factors include sunlight overexposure, presence of burns scars or chronic inflammatory lesions and chemical and actinic keratoses. Association of vitiligo and SCC has been a subject of controversy. Actinic damage in long lasting vitiliginous skin would be expected due to absence of melanin in the involved skin. Clinical experience and review of literature,

however, show that skin cancers and solar keratoses are rare findings in sun exposed vitiligo skin. Highest cure rates for early stage NMSC are achieved using Mohs micrographic surgery, which is considered the gold standard. However, surgical procedure causes significant disfigurement and functional impairment. Therefore in era of organ preservation, a non- invasive method of treatment is often preferred. Radiotherapy using brachytherapy technique is a well-established option as regards to acceptability and outcome of treatment in terms of local control, cosmesis and hand function. We report a case of generalized

vitaligo with cutaneous SCC of the hand treated with surface mould brachytherapy.

### Case report

A 61-year-old Indian man presented with generalized vitiligo since 45 years and a non-healing ulcer on the volar aspect of fourth finger of the right hand of 6 months duration. Vitiligo was bilaterally symmetrical involving upper limbs (including hands), lower limbs, large areas on the trunk and lower lip (fig1). The patient had been a tractor mechanic for past 35 years, which forced him to work outdoors in the sun for long hours and prolonged exposure to mineral oils (diesel). Despite long standing vitiligo, he had taken no specific treatment or photoprotection measures. He was a non smoker with no history of exposure to PUVA or X-rays and insignificant past medical or surgical history. No history of allergy to any substance could be elicited.

He had noticed a small asymptomatic erythematous, scaly papule on the volar aspect of fourth finger of the right hand about an year ago before clinical presentation which subsequently ulcerated 6 months later due to self-inflicted trauma, in an attempt to remove the lesion in totality. The resultant non-healing ulcer was painless. On clinical examination, 2 x 1.5 cm irregular, superficial ulcer on the volar aspect of the distal phalynx of fourth finger of the right hand with everted edges was appreciated. It's floor was necrotic with sparse granulation tissue and had a firm base with 3 mm depth as measured with calipers (fig 2). Multiple erythematous plaques and nodules, some with dry adherent crusting, were present on dorsal surface of both the hands.

A biopsy performed from the margin of the ulcer showed keratin pearls, nuclear hyperchromatism and pleomorphism with increased nucleocytoplasmic ratio of the squamous epithelial cells confirming it as well differentiated keratinizing SCC. The tumour was infiltrating dermis with no perineural invasion (fig 3).

Biopsy from two other sites was taken from the lesions on the dorsum of right hand which revealed hyperkeratosis, parakeratosis along with basophilic degeneration of dermal collagen and mild dermal lymphohistiocytic infiltrate suggestive of degenerative changes associated with solar elastosis.

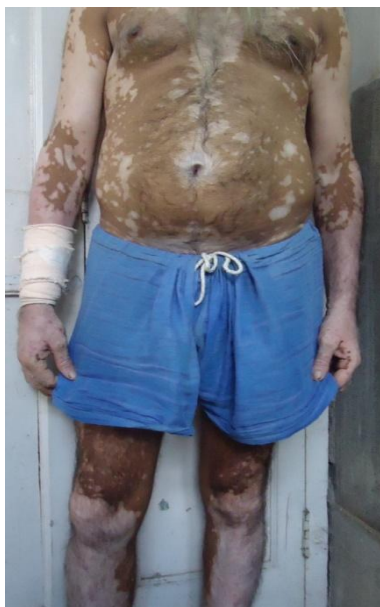A thorough clinical examination and loco-regional ultrasound study excluded lymph nodal involvement. There was no involvement of the underlying bone on radiography. Whole abdomen ultrasound examination and chest radiograph excluded distant metastases.

After discussing the various treatment modalities including possible amputation of the involved finger, patient opted for conservative management and preservation of limb. Radiation Oncology opinion was sought for and it was opined that patient be treated with high dose rate surface-mould brachytherapy because of its location leaving surgery as a salvage option.

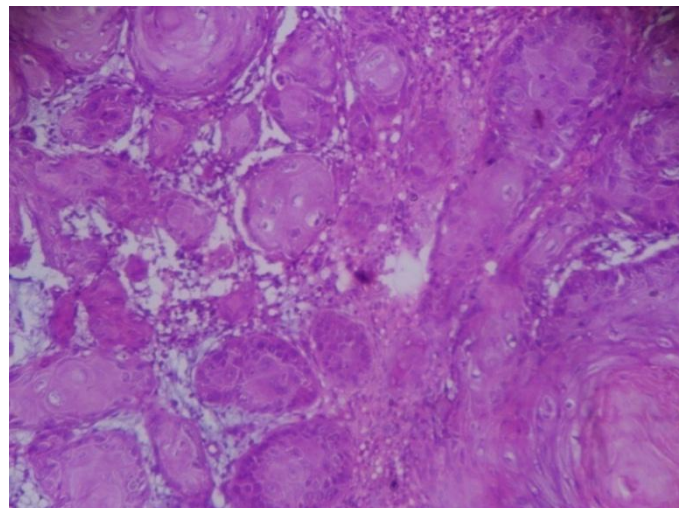
External Beam Radiotherapy can be delivered by low energy photons or electrons. However, this poses significant problems in ensuring proper dosimetry in a curved surface, conformity of small sized collimators and possibility of increased complications due to thinned out surface. Customized surface moulds overcome these potential issues. Considering all such factors, high dose rate remote after-loader brachytherapy with Ir 192 (Nucletron BV, Elekta, Veenendal, The Netherlands) was chosen.

An impression of the finger was taken in alginate used for dental implants. Before it was set, three one ended plastic catheters were set and dried corresponding to the tumor location( fig 4). The aim was to treat the entire tumor surface inclusive of margins and relay of the radioactive source through the plastic tubing. The surface mould was checked for consistency of fit and subsequently two isocentric radiographs were acquired keeping dummy catheters in situ. The implant geometry was reconstructed on the treatment planning system (Nucletron Plato v. 14.3) (Nucletron BV). The source loading was done in accordance with

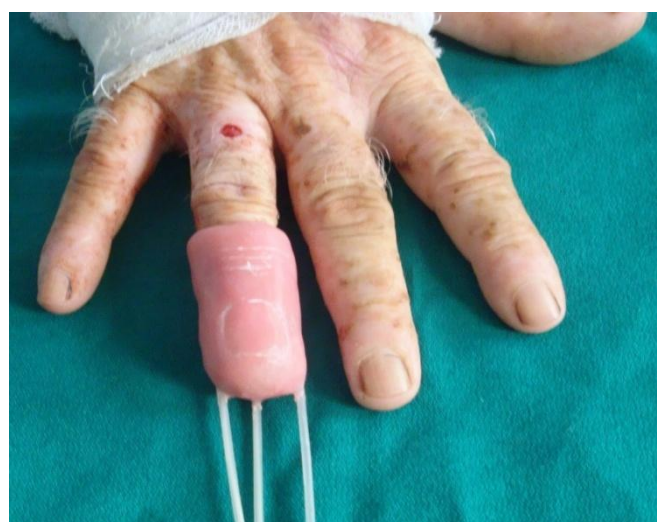Paris System rules. 45Gy to 5mm of the skin was prescribed such as 100% isodose covered the skin surface and 85% isodose to 5mm below the surface. 5Gy per fraction was delivered daily over 11 days. Following the course of brachytherapy, patient was followed up in outpatient department and topical emollients and antibiotics were prescribed. Follow up at 3 months of completion of treatment showed complete healing of malignant ulcer (fig 5). Further follow up at 1 year showed no recurrence.



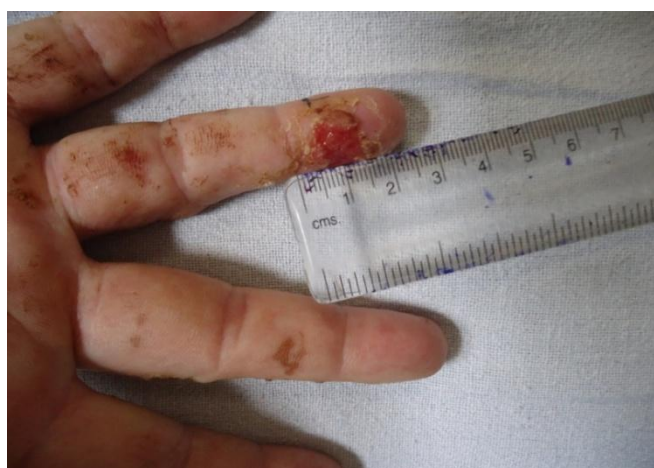**Figure 1** - Patient of generalized vitiligo with bilaterally symmetrical involvement of upper limbs, lower limbs and trunk.



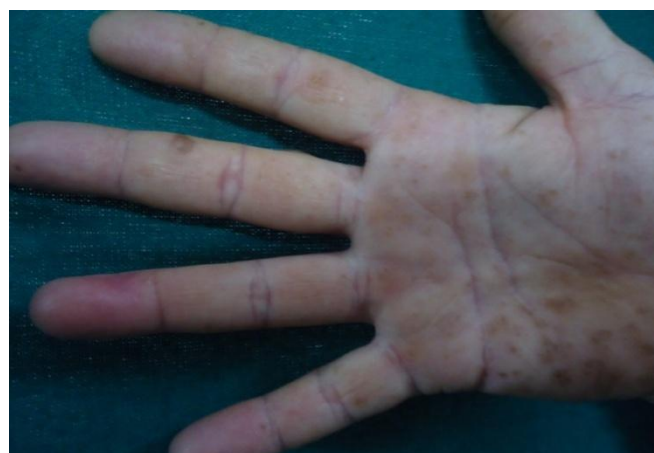**Figure 3** Histopathology of the ulcer showing nests of atypical epithelial cells in the epidermis and dermis with keratin pearls (H and E, x 40).



**Figure 4** – Surface mould constructed over the finger for the delivery of high-dose-rate brachytherapy.



**Figure 2** Volar aspect of the right fourth finger showing 2 x 1.5 cm irregular, superficial ulcer with everted edges, necrotic floor and scanty granulation tissue.



**Figure 5** – Follow up at 3 months of completion of treatment showing complete healing of the malignant ulcer.



## Discussion

Non melanoma skin cancer (NMSC) is the most common malignancy of the hand of which SCC accounts for 75-90%, followed by Basal Cell Carcinoma (BCC).<sup>1</sup>

Fitzpatrick skin phototypes V and VI, with high levels of constitutive pigmentation, have the lowest incidence of skin cancer as melanin is thought to be protective against the harmful effects of ultraviolet (UV) radiation. Therefore, a complete lack of melanin in vitiligo is expected to increase the deleterious effect of UV light, that might lead to development of skin cancer.<sup>2</sup> However, on the contrary, only few reports of NMSC in patients with vitiligo have been published.<sup>3</sup>

Tendency to avoid sun exposure, in patients of vitiligo, may be a reason for infrequent development of skin cancers in these patients. Thus chronic sun exposure may have been overlooked as a risk factor for developing SCC in a patient with vitiligo.<sup>4</sup> Other factors contributing to actinic damage in sun-exposed vitiligo skin may be duration of disease and intensity of ultraviolet (UV) exposure.<sup>5</sup> Our patient had received high and prolonged doses of UV light because of his occupation.

However, in a recent study conducted by Hexsel et al. in a cohort of 477 patients with vitiligo compared with two general US population, an increased or equal risk of NMSC in patients with vitiligo was seen.<sup>6</sup>

Therefore, in our patient, SCC and actinic keratosis developed in a long standing vitiligo skin due to chronic sun exposure for a long period of 35 years. Another particular risk factor that may have contributed for the development of SCC could be chronic exposure to polycyclic aromatic hydrocarbons (PAH) (mineral oils) as these have been implicated as predisposing factors for increased risk of development of skin cancer as substantiated by previous studies.<sup>7,8</sup>

Various methods to manage early stage NMSC are: surgery, electrodesiccation and curettage, cryotherapy, radiotherapy, photodynamic therapy

and pharmacological therapy (imiquimod). The goal of treatment is complete eradication of the tumour along with satisfactory cosmesis and preservation of hand function.<sup>9</sup> Mohs micrographic surgery has been advocated as the gold standard for NMSC. However, surgical procedures cause significant disfigurement and functional impairment. Therefore, in the era of organ conservation, where mutilating surgeries are considered retrogressive, alternative treatment modality such as radiotherapy is an option to consider.

The largest review by Hass et al, for 12 patients with SCC of the nail bed treated with primary radiotherapy, revealed 92% local control rate.<sup>10</sup>

Different techniques of radiotherapy have been used in treatment of NMSC- external beam radiotherapy and brachytherapy-with acceptable outcomes. Brachytherapy modality involves use of surface applicators in direct contact with the tumor. Tumoral control rates with this modality are similar to external radiotherapy but the overall treatment time is shortened. Therefore brachytherapy is ideal alternative for elderly patients with small and superficial tumors who are not fit for aggressive surgical management.<sup>9</sup>

Brachytherapy has very low rates of adverse events over long term. With this technique, recurrence rates are also low.<sup>11</sup>

Surface mould brachytherapy was chosen as the modality of treatment in our patient because it was a small and superficial tumor, and the treatment preserved hand function and cosmesis.

## Conclusion

Our patient, a known case of long standing generalized vitiligo developed actinic damage and SCC of the hand. The probable risk factors were- chronic sun exposure in depigmented skin along with prolonged exposure to aromatic hydrocarbons (diesel). Patient was treated with surface mould brachytherapy as morbidity with this therapeutic approach is low, and cosmesis and hand function after treatment are excellent. The purpose of sharing this case is to know that such

patients to be referred by the dermatologist to radiotherapy department instead of surgery.

## References

1. Somanchi BV, Stanton A, Webb M, Lancaster J, Allan E, Muir LTSW. Hand function after high dose rate brachytherapy for squamous cell carcinoma of the skin of the hand. *Clinical oncology* (2008) 20: 691-697.
2. Calanchini-Postizzi E, Frenk E. Long term actinic damage in sunexposed vitiligo and normally pigmented skin. *Dermatologica* 1987;174:266-71.
3. Hexsel CL, Eide MJ, Johson CC, Krajenta R, Jacobsen G, Hamzavi I, Lim HW. Incidence of non melanoma skin cancer in a cohort of patients with vitiligo. *J Am Acad Dermatol*. 2009 Jun;60(6):929-33.
4. Seo SL, Kim IH. Squamous cell carcinoma in a patient with generalized vitiligo. *J Am Acad Dermatol*. 2001 Dec;45(6 Suppl):S 227-9.
5. Saarinen K, Lestringant GG, Masouye I, Frossard PM. Actinic damage and squamous cell carcinoma in sun-exposed skin affected by vitiligo. *Br J Dermatol*. 2000 Jul;143(1):219-21.
6. Hexsel CL, Eide MJ, Johson CC, Krajenta R, Jacobsen G, Hamzavi I, Lim HW. Incidence of non melanoma skin cancer in a cohort of patients with vitiligo. *J Am Acad Dermatol*. 2009 Jun;60(6):929-33.
7. Kubaseiurcz M, Starzynski Z, Szymczak W. Case-referent study on skin cancer and its relation to occupational exposure to polycyclic aromatic hydrocarbons. II. Study results. *Pol J Occup Med Environ Health* 1991;4(2):141-7.
8. Jarvholm B, Easton D. Models for skin tumor risks in workers exposed to mineral oils. *Br J Cancer*. 1990 Dec;62(6):1039-41.
9. Montero A, Hernanz R, Capuz A. High-dose-rate (HDR) brachytherapy with custom-made moulds for the treatment of non-melanoma skin cancer. *ClinTranslOncol* (2009) 11:760-764.
10. Grootenboersa D, Poortmansa P, Haas R. Radiotherapy preserves fingers in the management of subungual squamous cell carcinoma, obviating the need for amputation. *Radiotherapy and Oncology* 85 (2007) 473-476.
11. Alam M, Nanda S, Mittal BB, Kim NA, Yoo S. The use of brachytherapy in the treatment of nonmelanoma skin cancer: a review. *J Am Acad Dermatol* 2011; 65: 377-88.