



## Tuberculosis –One of the Important Causes of Retroperitoneal Fibrosis in India

Authors

**M. Nagaprasanth<sup>1</sup>, P. Rajeshwari<sup>2\*</sup>, P.R. Prasad<sup>3</sup>, Salma Mahaboob R<sup>4</sup>**

<sup>1</sup>Assistant Professor in Urology at Chalmeda Anand Rao Institute of Medical Sciences, Karimnagar, Telangana, India

<sup>2</sup>Associate Professor in Biochemistry at Fathima Institute of Medial Sciences, Kadapa, Andhra Pradesh, India

<sup>3</sup>Professor in Biochemistry at Apollo Institute of Medical Science and Research, Chittoor, Andhra Pradesh India

<sup>4</sup>Assistant Professor in Biochemistry at Fathima Institute of Medial Sciences, Kadapa, Andhra Pradesh India

\*Corresponding Author

**P. Rajeshwari**

Associate Professor in Biochemistry at Fathima Institute of Medial Sciences, Kadapa, Andhra Pradesh, India

Email: [prasanthmammila@yahoo.com](mailto:prasanthmammila@yahoo.com)

### Abstract

**Introduction:** Retroperitoneal fibrosis (RPF) is an uncommon condition in which a predominantly inflammatory plaque encasing the aorta, inferior vena cava, ureters, other retroperitoneal structures. A definitive etiology of RPF is found in only 30% of cases. In patients with secondary RPF 8-10 % has been reported to have malignant etiology.

**Materials and Methods:** Between 2003 and 2011 we have treated 14 cases of RPF at our institute who had presented with renal failure. Eleven patients underwent surgical exploration and specimen sent for histopathological examination. Only DJ stenting in 2 patients. One had PCN. One patient died with hyperkalemia preoperatively, one after completion of chemotherapy, Post operatively treated with steroids for 1 year.

**Results:** In all cases renal parameters optimized with bilateral (B/L) DJ stenting. Out of 12 cases, 7 patients underwent ureterolysis with intraperitonealization, B/L ureterolysis with boari flaps in two patients, ureterolysis with uretero ureterostomy in one patient, Unilateral ureterolysis in one patient, only b/l dj stenting in 1 patient.. Histopathological examination showed Non hodgkin's lymphoma (NHL) in three cases, Tuberculosis in three cases, Non specific inflammation (Idiopathic) in 6 cases. one patient on b/l dj stents got symptomatic relief with ATT. Peritoneal biopsy revealed tuberculosis

**Observations:** In our series of RPF malignancy contributes 25% of cases and tuberculosis was seen in 25%. Surgical exploration has better outcome in cases of RPF regardless of aetiology to exclude malignancy and to prevent end stage renal disease. Long-term follow-up of these cases is warranted.

**Keywords:** retroperitoneal fibrosis, ureterolysis, intraperitonealization.

## Introduction

Retroperitoneal fibrosis is an uncommon condition in which a fibrotic and inflammatory mass envelops and potentially obstructs retroperitoneal structures, including either or both ureters. The initial report is now attributed to Albarran (1905), although idiopathic retroperitoneal fibrosis has had the eponym Ormond disease, after that author's description and definition of this clinical entity in 1948 (Albarran, 1905; Ormond, 1948). Grossly, retroperitoneal fibrosis appears as a fibrous, whitish plaque that encases the aorta, inferior vena cava, and their major branches, and also the ureters,<sup>(1)</sup> other retroperitoneal structures, and, at times, intraperitoneal structures including the gastrointestinal tract RPF may be an immune-mediated periaortitis.<sup>(2)</sup>

RPF most commonly affects patients who are 40 to 60 years of age with incidence of 1 in 200,000 to 1 in 400,000. RPF has male preponderance with a male to female ratio of 2 to 3:1. Only 30% of RPF patients will have an identifiable cause. Most common are drugs such as Methysergide, ergot alkaloids,  $\beta$  Adrenergic blockers, phenacetin etc. 8-10 % have been reported to have malignant etiologies such as lymphoma etc. Radiation therapy, Abdominal aortic aneurysm and Infectious causes such as Tuberculosis, Actinomyces, gonorrhea, or schistosomiasis etc. RPF may be an immune-mediated periaortitis.<sup>(2)</sup> In Indian scenario Tuberculosis may be one of the important cause of RPF. In most patients, the presenting symptom is pain in the lower back and/or flank. Other symptoms include weight loss, anorexia, nausea, generalized malaise, fever, hypertension, and oliguria/anuria.

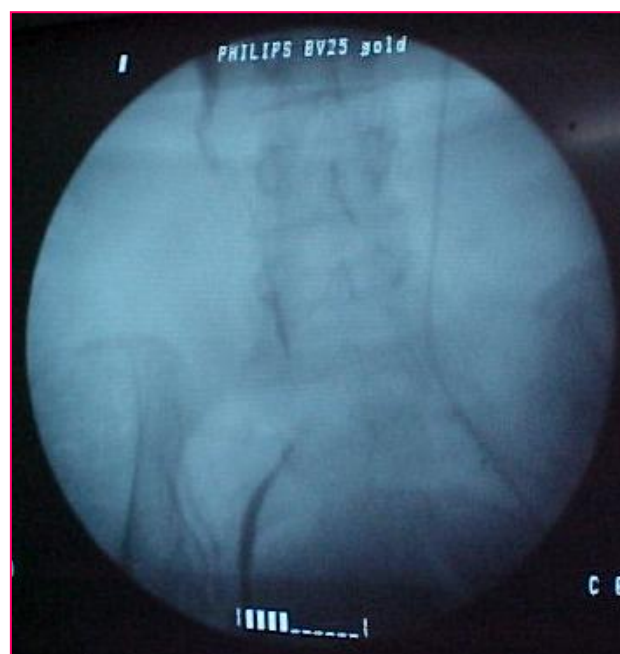After performing temporizing measures for ureteral obstruction that threatens renal function, diagnosis of malignant or benign etiology is the first step toward definitive management of this problem. Following bilateral ureterolysis, the ureters should be repositioned and protected from further fibrous entrapment. Several surgical options are available. One option is to retract the

ureters laterally and secure the overlying peritoneum medially to the psoas muscle to maintain the ureters in this location. Another option is to close the peritoneum behind the ureters so that the ureters may be displaced anteriorly into the peritoneal cavity.<sup>(3,4)</sup>

## Materials and Methods

Between 2003 and 2011 we have treated 14 cases of RPF at our institute who had presented with renal failure. Detailed history, renal parameters, urine chemistries and appropriate imaging study were done in all cases. All the patients were stabilized with B/L DJ stenting and one undergone Rt PCN, as dj stenting was not possible. Renal parameters were stabilized.

Eleven patients underwent surgical exploration and specimen sent for histopathological examination. Only DJ stenting in 2 patients. one had PCN. out of 14 patients, 2 died. One patient died with hyperkalemia preoperatively, one after completion of chemotherapy, one patient on b/l dj stents got symptomatic relief with ATT. Post operatively treated with steroids for 1 year.



**Fig 1** Retrograde pyelography typically demonstrates hydronephrosis, with medially deviated and segmentally narrowed ureters without filling defects

## Results

In all cases renal parameters optimized with bilateral (B/L) DJ stenting. Out of 12 cases, 7 patients underwent ureterolysis with intraperitonealization, B/L ureterolysis with boari flaps in two patients, ureterolysis with uretero ureterostomy in one patient, Unilateral ureterolysis in one patient, only b/l dj stenting in 1 patient. Histopathological examination showed Non hodgkin's lymphoma (NHL) in three cases, Tuberculosis in two cases, Non specific inflammation (Idiopathic) in 6 cases. One patient on b/l dj stents got symptomatic relief with ATT. Peritoneal biopsy revealed tuberculosis. NHL case is being treated with CHOP chemotherapy

**Table 1**

Procedure	No of cases
B/L ureterolysis with intraperitonealization	7
B/L ureterolysis with boari flaps	2
B/L ureterolysis with uretero ureterostomy	1
Unilateral ureterolysis	1
Only DJ stenting	2
PCN	1

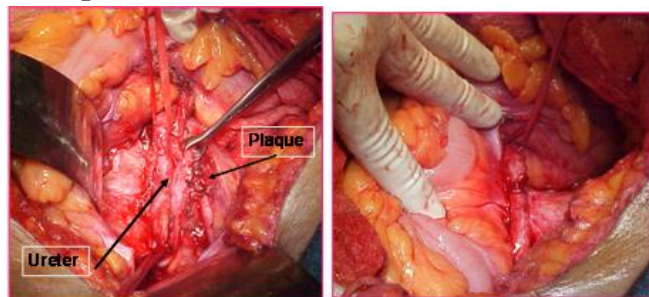
**Table 2**

### Histopathological examination

HPE	No of cases
Non hodgkin's lymphoma (NHL)	3
Tuberculosis	3
Non specific inflammation (Idiopathic)	6

14

### Intraperitonealization



**Fig 2**

## Discussion

RPF usually presents with low back pain. Retrograde pyelography typically demonstrates hydronephrosis, with medially deviated and segmentally narrowed ureters without filling defects. Currently, cross-sectional imaging with CT or MRI is the modality of choice for evaluating patients with suspected retroperitoneal fibrosis. CT typically reveals a well demarcated retroperitoneal mass, isodense with muscle on unenhanced studies.<sup>(5)</sup> In tuberculous RPF, mass is mainly fibrotic with entrapment of ureter. Hence during surgery there is high chance of ureteric injury and necrosis. Surgical exploration and various immunosuppressive therapies, combined with ureteral decompression have been recommended in RPF. The conventional treatment of ureteric obstruction has been ureterolysis. The ureter may be displaced to a lateral position, brought to an intraperitoneal location by closing the peritoneum behind it, or wrapped within a sleeve of omentum. The success of ureterolysis reported as 66% to 100%. One-year treatment with prednisone is associated with a high rate of initial success, but a high recurrence rate<sup>(6)</sup>. Surgical exploration followed with prednisolone has low rate of recurrence rate.

Tuberculosis is one of the rare causes of RPF but in countries like India it may be one of the important causes of RPF. Tuberculosis with features such as bilateral lower ureteric strictures (medial deviation of ureters) should have high suspicion of RPF and should be explored.

## Observations

In our series of RPF malignancy contributes 25% of cases and tuberculosis was seen in 25%. Surgical exploration has better outcome in cases of RPF regardless of aetiology, to exclude malignancy & tuberculosis and to prevent end stage renal disease. High predictive suspicion of RPF should be present in long ureteral strictures. Steroids may be a useful adjunct to ureterolysis in the treatment of this condition. Long-term follow-up of these cases is warranted.

**Conclusions**

Surgical exploration followed by steroids is the preferred treatment for RPF.

RPF due to tuberculosis should be suspected in patients with long ureteral strictures.

**References**

1. Lepor and Walsh, 1979; Koep and Zuidema, 1987
2. Kearney et al, 1976; Baker et al, 1987; Adam et al, 1998; Higgins et al, 1998; Van Bommel, 2002; Fry et al, 2008
3. Tresidder et al, 1972
4. Varkarakis and Jarrett, 2005
5. Vivas et al, 2000
6. American Journal of Kidney Diseases, Vol 49, No 5 (May), 2007.