



A Rare Case of Bilateral Hernia of Canal of Nuck

Authors

**Dr Arvind Kumar Prabhat¹, Dr Niranjan Dash², Dr J.M. Gadekar³,
Dr Mrs. V.J.Thipse⁴**

¹Postgraduate Student, ²Professor, ³Professor and Head of Department, ⁴Professor
Department of General Surgery, DVVPF'S Medical College and Hospital, Ahmednagar, Maharashtra, India

Abstract

Inguinal hernia is quite uncommon in female, as compared to in males because of stronger inguinal anatomy in female. Rare in paediatric age group. We report a case of 7 year old female patient who presented to our hospital with bilateral inguinal hernia. She underwent hernia repair. On inguinal exploration, hernia sac on right side was containing an unusual content as ovary and on the left side hernia sac was containing small bowel loops. Hernia sac was transfixed after reduction of its contents. She had a smooth post operative course. There is no recurrence during one year of follow up.

Keywords: *Inguinal hernia, Ovary, Hernia repair, Canal of Nuck.*

Introduction

Inguinal hernias are rare in females. The Incidence of female inguinal hernia is 1.9%. The Male:Female ratio for inguinal hernias is 7 : 1.^(1,2) Inguinal hernia on the right side being presented in 68.1%, on the left side in 23.4% and bilateral in 8.5%.⁽³⁾ The female inguinal hernial sac in about 15-20% cases contain ovary and fallopian tube.⁽⁴⁾ Female inguinal Hernia sac in few cases contain the both ovaries and the uterus.⁽⁴⁻⁹⁾

In females, the indirect inguinal hernia is due to congenital weakness at the deep inguinal ring. The canal of Nuck, first described by Anton Nuck (de) in 1691, is an abnormal patent pouch of peritoneum extending into the labia majora of female (Fig.1). It is analogous to a patent processus vaginalis in males. Female inguinal hernia is caused by a failure of obliteration of the canal of Nuck.⁽¹⁰⁾

In our case, she was 7 year old female with bilateral inguinal hernia containing the ovary on the right side and small bowel loops on the left side. The clinical significance is discussed.

Case Report

A 7- year-old female child, presented to the surgical department in DVVPF'S Medical college and Hospital along with her mother with bulge on both the groin since 1 year and with mild bilateral groin pain since 5 days. The swelling was reduced on lying down and appeared on coughing. The female child was born full term normal delivery. On examination there was bilateral non-tender inguinal swelling .Deep ring occlusion test was positive and expansile cough impulse was present. There was no signs of strangulation. Examination of rest of the abdomen was normal.

Ultrasound revealed that there is defect in anterior abdominal wall on both sides measuring 1.8 cm

on the right side and 1.4 cm on the left side suggestive of bilateral inguinal hernia. On the left side there is herniated small bowel loop showing normal vascularity and peristalsis, and on the right side there is ovary as the content. Colour Doppler showed normal blood flow to the herniated ovary. Routine investigations were normal.

Pre anaesthetic check up was done and patient was taken up for surgery. On exploration, patient was found to have small bowel loops on the left side and ovary on the right side in the hernia sac. The hernia sac contents were reduced back into the peritoneal cavity. The sac was transfixed at the base by vicryl suture 3.0 and redundant sac was excised. The wound was closed in layers. The immediate postoperative was uneventful. Oral feeds were started after 6 hours. The patient recovered satisfactorily and was discharged after removal of skin sutures on 8th postoperative day. During the follow-up visit in surgical OPD, the operative scar was found to be well healed and there was no recurrence after 1 year of follow up.

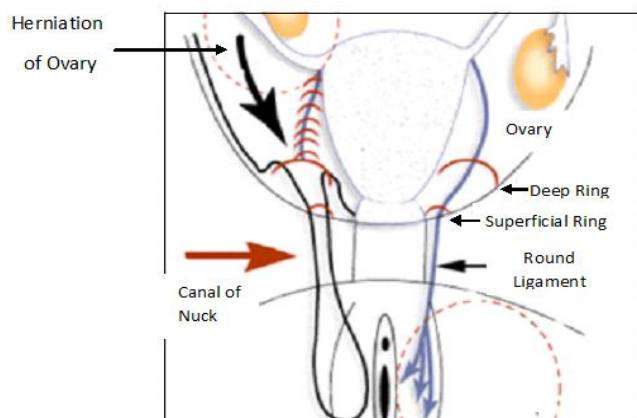


Figure 1 : Herniation of ovary through canal of Nuck




Figure 2: Groin Bulge

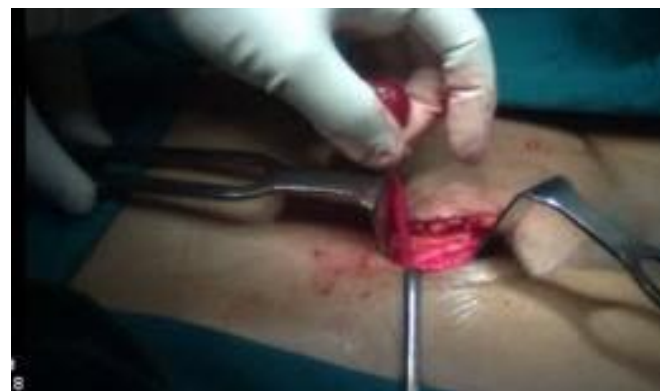

Figure 3: Herniotomy under progress

Discussion

Inguinal hernias rarely occur in females. The life time risk of inguinal hernia is 3% in female.⁽¹¹⁾ The most common sub type of groin hernia in female is the indirect inguinal hernia.⁽¹²⁾ Inguinal hernia is a most common problem in the surgery with its unusual content ,may sometime surprise the surgeons .^(13,14)

Hernia of canal of Nuck is an abnormal extension of peritoneal fold extending into the labia majora of female through the inguinal canal, which accompanies round ligament of uterus. This extension of peritoneal fold obliterates by 8th month of intrauterine life and failure or incomplete obliteration leads to hernia of canal of Nuck.⁽¹⁵⁾ It is analogous to processus vaginalis in males.

One of the published reports laid the hypothesis that if there is failure of the fusion of the Mullerian Duct leading to the excessive mobility of the ovaries and non fusion of the uterine cornuae, the chance of herniation of the ovary into the inguinal canal is increased.⁽¹⁶⁾

The risk factors of female inguinal hernia are like obstipation and positive family history. Small musculo-pectineal orifice of Fruchaud in female is a weak spot from where hernia can occur, which can be strengthened with controlled strenuous activity. Sports activities are protective for inguinal hernia.⁽¹⁷⁾

Once the diagnosis of the inguinal is made in female, repair should be carried out promptly because incarceration occurs in the 1st year of life is more.⁽¹⁹⁾ Incarceration of ovary leading to

torsion has been reported.⁽¹⁹⁾ In our case fortunately, there was no complication prior to surgery.

Hydrocele of canal of Nuck is the most common differential diagnosis of the hernia of canal of Nuck. Other differential diagnosis would be Lipoma, Bartholin's cyst, Post traumatic hematoma, Cold abscess, Lymphadenopathy, rarely Cystic Lymphangioma, Ganglion and Neuroblastic metastasis to groin.⁽²⁰⁾

The diagnosis of hernia of canal of Nuck in female is based on clinical presentation, physical finding and ultrasonography. USG is a very effective tool to detect prolapsed organs in inguinal hernia.⁽⁴⁻⁹⁾

In female, the round ligament of the uterus goes from the pelvis, passes through the deep inguinal inguinal ring and runs along the inguinal canal and terminates in the hernial sac, is actually the suspensory ligament of the ovary.⁽²¹⁾

In our case the right inguinal hernia sac contains only ovary which could be due to long ovarian ligament and broad ovarian mesentery. The hernia sac was explored and walls inspected for a sliding component. The mesenteric attachment to the inner hernia sac wall was dissected in the bloodless plane. The ovary was then reduced with no compromise in the blood supply, and the base of sac was transfixed. The left inguinal hernia sac contained the small bowel loops. The reduction of content was done and base of sac transfixed.

When the female inguinal hernia is bilateral then it should raise the Surgeon's suspicion about the child's nuclear sex, because of absence of androgen responsiveness i.e, Androgen Insensitivity Syndrome.⁽²²⁾ In our case there was no such positive finding.

Conclusion

Inguinal hernia occurs rarely in females. The sliding hernial sac contents like fallopian tube, ovaries, uterus and small bowel loops should be evaluated carefully. All patients of female inguinal hernia should undergo USG to see the genital structures. If the hernial sac contains the

genital structures, hernia repair should be carried out immediately to avoid the complications.

Ethical approval

Written informed consent was obtained from the patient for publication of this case report and accompanying images. A copy of written consent is available for review by the Editor-in-Chief of this journal.

References

1. V. M. J. Sherman and F. C. Brunicardi, "Inguinal hernias," in *Schwartz's Principles of Surgery*, McGraw-Hill, New York, NY, USA, 2015;10:1495-1519.
2. Sangwan M, Sangwan V, Garg M, Mahendirutta P, Garg U. Abdominal wall hernia in rural population in India-spectrum changing? *Open J Epidemiol* 2013;3:135-8.
3. Devlin HB. Inguinal hernia in babies and children. In: Dudley H, Walter P, Carter D, eds. *Rob & Smith operative surgery*. Oxford: Butterworths, 1983;4:449-54.
4. Cascini V, Lisi G, Di Renzo D, et al. Irreducible indirect inguinal hernia containing uterus and bilateral adnexa in a premature female infant: report of an exceptional case and review of the literature. *J Pediatr Surg* 2013;48:17-19.
5. Artas H, Gurbuzer N. Inguinal hernia containing both ovaries and the uterus in an infant. *J Ultrasound Med* 2012;31:1137.
6. Graves GY, McIllovey DB, Green B. Hernia of uterus, ovaries and tubes in a sixweek old infant. *J Dis Child* 1951;81:250.
7. Wiley J, Chavez HA. Uterine adnexa in inguinal hernia in infant females. *West J Surg Obstet Gynecol* 1957;65:283.
8. Anatoly AG, Marshall DG. Incarcerated direct inguinal hernia containing uterus, both ovaries, and fallopian tubes. *J Pediatr Surg* 1986;21:986.

9. Okada T, Sasaki S, Honda S, Miyagi H, Minato M, Todo S. Irreducible indirect inguinal hernia containing uterus, ovaries, and Fallopian tubes. *Hernia* 2012;16:471.
10. Gurudutt Bhaskar Basrur, Bilateral inguinal hernias containing ovaries, clinics and practice 2015;5:708
11. Gould J. Laparoscopic versus open inguinal hernia repair. *Surg Clin N Am*. 2008;88:1073-1081.
12. Rutkow IM. Epidemiologic, economic, and sociologic aspects of hernia surgery in the United States in the 1990s. *Surg Clin North Am*. 1998;78:941.
13. A. Gurer, M. Ozdogan, N. Ozlem, A. Yildirim, H. Kula-coglu and R. Aydin, "Uncommon Content in Groin her-nia Sac," *Hernia*, 2006;10:152-155.
14. K. Ballas, T. H. Kontoulis, C. H. Skouras, A. Triantafyl-lou, N. Symeonidis, T. H. Pavlidis, *et al.*, "Unusual Find-ings in Inguinal Hernia Surgery. Report of 6 Rare Cases," *Hippokratia*, 2009;13:169-171.
15. Jedrzejewski G, Stankiewicz A, Wieczorek AP. Uterus and ovary hernia of the canal of Nuck. *Pediatr Radiol* 2008;38:1257-8.
16. Dr Sumita A Jain, Sliding Inguinal Hernia in Elderly Female With Ovary as its Content; *ARC Journal of Clinical Case Reports*, Issue 1, 2015;1:21-23
17. Huang CS, Luo CC, Chao HC, Chu SM, Yu YJ, Yen JB. The presentation of asymptomatic palpable movable mass in female inguinal hernia. *Eur J Pediatr* 2003;162:493-5.
18. Chawla S. Inguinal hernia in females. *Med J Armed Forces India* 2001;57:306-8.
19. Merriman TE, Auldist AW. Ovarian torsion in inguinal hernias. *Pediatr Surg Int* 2000;16:383-5.
20. Poenaru D, Jacobs DA, Kamal I. Unusual findings in the inguinal canal: A report of four cases. *Pediatr Surg Int* 1999;15:515-6.
21. Ando H, Kaneko K, Ito F, et al. Anatomy of the round ligament in female infants and children with inguinal hernia. *Br J Surg* 1997;84:404-9.
22. Siddaiah B. XY female with complete androgen insensitivity syndrome with bilateral inguinal hernia. *J Indian Med Assoc* 2013;111:480-1.