



## Correlation of Uveitis with presentation of Ankylosing Spondylitis in Central India

Authors

**Dr Akshat Pandey<sup>1</sup>, Dr VP Pandey<sup>2</sup>**

<sup>1</sup>Consultant Rheumatologist, Apollo Hospitals, Indore, India

<sup>2</sup>Professor of Medicine & Consultant Rheumatologist, Dept. of Medicine, MGMMC, Indore, India

\*Corresponding Author

**Dr Akshat Pandey**

Phone number: +919926084007, Email: [drakshat23@gmail.com](mailto:drakshat23@gmail.com)

### ABSTRACT

**Introduction:** *There have been many studies of association of Uveitis in cases of Ankylosing spondylitis but few of them only discussed the risk factors which could be associated with occurrence of Uveitis in AS. The study analyzed the risk factors of uveitis in patients with Ankylosing spondylitis.*

**Material and Methods:** *Total of 290 patients with AS were taken from September 2016 to June 2017. Retrospectively records were reviewed and information was collected accordingly, such as duration of disease, HLA-B27, and the number of patients with peripheral arthritis. Hip-joint lesion was seen by imaging. Biochemical examinations were performed to determine the patient's physical function.*

**Result:** *Of 290 patients with AS (82.8% male, mean age 31.2 years), 28 (9.6%) had experienced 1 or more episodes of uveitis (Figure.1). Incidence rate for hip-joint lesion was obviously higher for patients with uveitis than the nonuveitis group (46.4% vs 21.3%;  $P < 0.01$ ). Number of patients with peripheral arthritis were more for the uveitis group than in non-uveitis group ( $2.23 \pm 0.26$  vs  $0.52 \pm 0.03$ ;  $P < 0.001$ ). However, no significant differences in disease duration, HLA-B27, erythrocyte sedimentation rate (ESR), and C-reactive protein (CRP), was seen between these groups. Binary logistic regression results showed that the number of peripheral arthritis ( $OR = 3.9$ ,  $95\%CI: 2.6-6.3$ ,  $P < 0.01$ ) are significantly associated with uveitis in AS.*

**Conclusion:** *Therefore Hip joint lesion, peripheral arthritis could be associated with higher levels of Uveitis in cases of Ankylosing spondylitis and the possible occurrence of uveitis in AS should not be neglected in these patients who have such risk factors.*

**Keywords:** *Ankylosing Spondylitis, Hip joint lesion, peripheral arthritis, risk factors, uveitis.*

### Introduction

Ankylosing spondylitis (AS) is one of the most common Inflammatory disorder which could affect peripheral as well as axial joints along with various Extra articular manifestations. Its pathogenesis isn't clear despite of important role of HLAB-27 which

has been reported since past 30-40 years in literature. Prevalence is 0.1% to 1.4% of the general population, and affects mostly the young adults of age between 20 and 30 years.<sup>[1]</sup> There are so many extra articular manifestations of AS which could affect multiple organs such as Lungs, Kidneys, Heart, Eyes etc. Acute anterior Uveitis is one of the

commonest manifestation which could be present in around 30% of patients with AS. Posterior Uveitis is rare in AS<sup>[2]</sup> Despite of high prevalence of Uveitis in AS there are very few studies which suggests of possible risk factors leading to occurrence of Uveitis and that could help us in predicting the occurrence of Uveitis in AS. Many of the times patients ocular symptoms are not typical thus it could be possibly misdiagnosed as Conjunctivitis due to symptoms of Lacrimation, redness of eyes and pain. In our study we tried to know the possible conditions which are associated with uveitis, to detect them early so that in future we can pick up the risk factors and spread the awareness regarding development of Uveitis in patients suffering from AS.

### Materials and Methods

AS patients were taken into target from a Rheumatology clinic in Indore(M.P),India from September 2016 till June 2017 . The study was approved by the ethics committee. All patients fulfilled the 1984 modified New York criteria.[3]No definite criteria is present for diagnosing Uveitis thus according to patients general symptoms and ocular complaints which was done by various ophthalmologists, Uveitis was diagnosed. Other inflammatory Autoimmune disorders were ruled out[4].Patients of AS with uvetiis and non uveitis were arranged in the respective groups. Medical records were retrospectively reviewed and the associated information such as Human leukocyte antigen B27 (HLA-B27) positive or negative, age,duration of the disease, gender and the number of peripheral arthritis were collected. Magnetic resonance imaging (MRI) was done to diagnose hip joint lesion. Various bio-chemical tests were performed. SPSS used to perform statistical analysis. Odds ratio (OR) was calculated using Logistic regression analysis of associated risk factors. A P-value of <0.05 was considered significant. Student's t test was used to perform the difference of measurement data comparison. For the ratio comparison Chi-Square Goodness-of-Fit test was

used. All the data were shown as mean±standard error.

### Result

In our study there were 290 cases who had Ankylosing spondylitis between the age of 16 and 55. Out of which 28(9.6%) who had 1 or more than 1 episode of uveitis were taken in the Uveitis group with an average of 32.9 years and a Sex Ratio(male/female) of 21:7(Table 1). In Non uveitis group there were 196 individuals with the average age of 31.2 years and a sex ratio (male/female) of 196:66. Out of these 28 cases in the uveitis group, 46.4% (13/28) were with hip joint involvement, whereas only 21.3% (56/252) of the non uveitis group suffered from lesion in hip-joint. Thus, In patients with uveitis in AS the incidence of hip-joint lesion involvement was significantly higher(P value <0.01). Also the number of patients with Peripheral arthritis was also larger was also more in the Uveitis group than the non uveitis (2.23±0.26 vs 0.52±0.03; P<0.001). No significant difference was observed in gender, age, disease duration, and HLA-B27 between these 2 groups. According to the results of biochemical examination (Table 2), there were no significant difference in inflammatory indices (ESR, CRP, PLT), liver function indexes (albumin, AST, ALT), renal function indexes (BUN, Scr) and Uric acid levels in the two groups. Binary logistic regression proved that the number of peripheral arthritis (OR=3.9, 95%CI:2.8-6.4, P<0.01) are significantly associated with occurrence of Uveitis in AS.

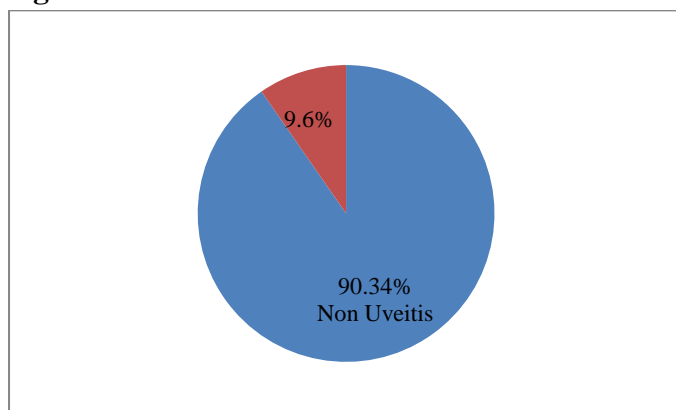
Clinical data of patients with AS.(Table 1)

	Non uveitis group(n=262)	Uveitis group(n=28)	P-value
Sex,Male/female	196/66	21/7	>0.05
Age,year	31.2±0.6	32.9±0.7	>0.05
HLAB27 (positive/negative)	250/16	20/8	>0.05
No. of Hip involvement	21.3%(56/252)	46.4%(13/28)	<0.01
No.of Peripheral arthritis	0.52±0.03	2.23±0.26	<0.001

AS=ankylosing spondylitis, HLA-B27=human leukocyte antigen B27

Occurrence of Uveitis in cases of Ankylosing Spondylitis.

**Figure 1**



**Lab Investigations.(Table 2)**

	Non uveitis group(n=262)	Uveitis group(n=28)	P-value
ESR, mm/h	40.6±2.1	39.6±5.9	>0.05
Platelet, 109/L	248.8±5.5	250.0±11.4	>0.05
ALT, U/L	256.2±0.6	22.3±2.4	>0.05
CRP, mg/L	18.8±2.3	19.6±2.8	>0.05
AST, U/L	17.9±1.5	21.9±2.7	>0.05
Albumin, g/L	46±0.5	46.6±0.7	>0.05
BUN, mmol/L	5.1±0.1	4.9±0.1	>0.05
Scr, mmol/L	65.8±0.9	71.0±0.8	>0.05
UA, mg/dL	3.09±0.06	3.05±0.18	>0.05

**Binary logistic regression analysis (Table 3)**

Risk factors	B	P	OR(Odds Ratio)	95% CI
Peripheral Arthritis	1.3	<0.01	3.9	2.8-6.4

## Discussion

The present study shows that in Ankylosing spondylitis, Uveitis is highly correlative of Hip joint lesion, and the number of peripheral arthritis. However, there is no association between HLAB-B27 and Uveitis till now. Uveitis is a condition defined by inflammation of the uvea, which consist of iris, ciliary body, and choroid. There is painful red eye, sensitivity to bright light(Intense photophobia), increased lacrimation, myosis, blepharospasm, and blurring of vision.<sup>[5]</sup> Our data show the strong correlation between uveitis in AS and the number of peripheral arthritis, suggesting that patients with severe peripheral joint involvement are more prone to develop uveitis. Yilmaz et al<sup>[6]</sup> reported patients with peripheral involvement had higher disease activity, functional impairment, metrologic indices, more severe pain,

night pain, and morning stiffness. And this finding was also supported by other studies.<sup>[7-9]</sup> This suggest that peripheral arthritis may be one of the reason for more aggressive outcome in cases of Ankylosing spondylitis. Maksymowych et al<sup>[10]</sup> and Sun et al<sup>[11]</sup> has a similar finding with our study. They proposed their opinion that patients with peripheral arthritis in AS are also susceptible to develop AAU, with no possible mechanism clarified yet. And their proposition was intensely supported by Singh et al<sup>[12]</sup> who reported that AS patients with peripheral arthritis had significantly higher prevalence of uveitis when compared with patients without peripheral arthritis. In our study, the prevalence of hipjoint lesion is 46.4% in the uveitis group, as compared to 21.3% in the nonuveitis group. About one-third of patients in AS may lead to hip disability and replacement in which hip joint lesion occur.<sup>[13]</sup> Therefore, as per our finding opinion can be proposed that AS patients associated with peripheral involvement or hip lesion, are more prone to develop uveitis.

In our study there were few limitations. First, there are no definite diagnostic criteria for uveitis and it is diagnosed by different ophthalmologists from 2 hospitals. Secondly, the number of enrolled AS patients is relative small, especially of the uveitis group, which may reduce the strength of our conclusion. Third, methods to access functional limitations and disease activity have not been used in our study, such as Ankylosing Spondylitis Quality of Life (ASQoL), Bath Ankylosing Spondylitis Disease Activity Index (BASDAI), Bath Ankylosing Spondylitis Functional Index (BASFI).

## Conclusion

Our study shows that there was a higher rate of Uveitis in AS in number of patients with peripheral arthritis, hip-joint lesion involvement, and the possible occurrence of uveitis in AS should not be neglected If patients have atypical ocular symptoms along with such risk factors. The ocular examination would be worthwhile to perform in such conditions. Meanwhile, other factors which possibly might lead to diagnosis of Uveitis must be further evaluated.

**Source(s) of support:** Nil

**Presentation at a meeting:** Nil

**Conflicting Interest (If present, give more details):** Nil

**Acknowledgement:** Nil

## References

1. Dakwar E, Reddy J, Vale FL, et al. A review of the pathogenesis of ankylosing spondylitis. *Neurosurg Focus* 2008;24:E2.
2. Gouveia EB, Elmann D, Morales MS. Ankylosing spondylitis and uveitis: overview. *Rev Bras Reumatol* 2012;52:742–56.
3. Wang F, Yan CG, Xiang HY, et al. The significance of platelet activation in ankylosing spondylitis. *Clin Rheumatol* 2008;27:767–9.
4. Selmi C. Diagnosis and classification of autoimmune uveitis. *Autoimmun Rev* 2014;13:591–4.
5. El MA. Extra-articular manifestations of ankylosing spondylitis: prevalence, characteristics and therapeutic implications. *Eur J Intern Med* 2011;22:554–60..
6. Yilmaz O, Tutoglu A, Garip Y, et al. Health-related quality of life in Turkish patients with ankylosing spondylitis: impact of peripheral involvement on quality of life in terms of disease activity, functional status, severity of pain, and social and emotional functioning. *Rheumatol Int* 2013;33:1159–63.
7. Bostan EE, Borman P, Bodur H, et al. Functional disability and quality of life in patients with ankylosing spondylitis. *Rheumatol Int* 2003;23: 121–6.
8. Aggarwal R, Malaviya AN. Clinical characteristics of patients with ankylosing spondylitis in India. *Clin Rheumatol* 2009;28:1199–205.
9. Dalyan M, Guner A, Tuncer S, et al. Disability in ankylosing spondylitis. *Disabil Rehabil* 1999;21:74–9.
10. Maksymowych WP, Chou CT, Russell AS. Matching prevalence of peripheral arthritis and acute anterior uveitis in individuals with ankylosing spondylitis. *Ann Rheum Dis* 1995;54:128–30.
11. Sun et al. *Medicine* (2016) 95:28
12. Singh G, Lawrence A, Agarwal V, et al. Higher prevalence of extraarticular manifestations in ankylosing spondylitis with peripheral arthritis. *J Clin Rheumatol* 2008;14:264–6.
13. Vander CB, Vastesaegeer N, Collantes-Estevez E. Hip disease in ankylosing spondylitis. *Curr Opin Rheumatol* 2013;25:448–54.