



Bile Duct Injuries Following Laparoscopic Cholecystectomy and their Outcome

Authors

Dr Manawor Ahsan¹, Dr Mohammad Eqbal Ahmad²

¹Assistant Professor, Dept. of Surgery, NCMH, Patna

²Associate Professor, Dept. of Surgery, NCMH, Patna

ABSTRACT

Introduction: Bile duct injuries are still among the most common and dreadful complications, following laparoscopic cholecystectomies despite advancement of training and technology.

Methods: Prospective study of bile duct injuries occurring in the period 2013 to 2015 at Nalanda Medical College Patna.

Results: in total, 40 patients (28 women and 12 men) with a median age of 45 (range 10–76) Years had a leak or a lesion of the bile ducts during the study period. Total incidence of Postoperative bile leaks or bile duct injuries was 0.9% and for bile duct injuries separately, 0.4%. Median delay from injury to repair was 5 days (range 0–68 days). In 12 patients (18%), the injury was discovered intraoperatively. Bile leak was the major symptom in 59%, and 52% had a leak from the cystic duct or from assumed aberrant ducts in the liver bed of the gall bladder. Following the clavien–dindo classification, 39% and 45% were classified as IIIA and IIIB, respectively, 10% as IV, and 6% as V. in all, 21 patients had injuries to the common bile duct or hepatic ducts, and in these patients, 21% were treated with a hepaticojejunostomy, 70% had an uncomplicated event, whereas 2.5% later on developed a stricture. Out of 21 patients with injuries to the cystic duct/aberrant ducts, 14 could be treated with stents or sphincterotomies and percutaneous drainage.

Conclusion: half of injuries following cholecystectomies are related to the cystic duct, and most of these can be treated with endoscopic or percutaneous procedures. A considerable number of patients following hepaticojejunostomy will later on develop a stricture.

Keywords: Laparoscopic cholecystectomy; bile duct injuries; complications; mortality.

Introduction

Laparoscopic cholecystectomy is one of the most commonly performed surgical procedures and since its introduction by Erich Muhe in 1985. The incidence of bile duct injuries were now decreasing due to improvement in the equipment and improved training in laparoscopy. The global incidence of CBD injury has remained fairly constant around 0.5% as reported by various meta-

analysis studied over a 15 year period. The treatment of bile duct injuries has changed since the introduction of laparoscopic surgery. Most bile leaks are now treated with endoscopic procedures like stents and endoscopic sphincterotomy, whereas the more severe cases will still need a repair of the common bile duct^(10, 11). Despite this, a rather high proportion of the patients will still have strictures and episodes of cholangitis⁽¹²⁾.

Following the introduction of laparoscopic surgery, several registries were established in order to monitor the evolvement of possible bile duct injuries.

Most of these aimed to evaluate the incidence and risk factors for complications, whereas rather few have looked into therapy and its outcome after treatment at Nalanda Medical College and Hospital we have evaluated the bile duct injury and its outcome following treatment.

Patients and Methods

This study represents a prospective database of all patients who developed bile leakage or bile duct injuries from 2013 to 2015 at Nalanda Medical College and Hospital, Patna. Majority of patients who developed bile duct injuries or bile leaks were treated at NMCH Patna. Some patients of bile duct injuries were sent to endoscopist for ERCP and stenting. Most of injuries are known to be caused by misidentification of anatomy and common cause of CBD injury is due to misidentification of CBD as cystic duct. Second misidentification injury involves the aberrant right hepatic duct present in 2% of patients. The direction of traction of GB contribute CBD injury. Excess traction and superior pull instead of lateral leads to appearance of CBD as cystic duct and causes injury. Acute and chronic inflammation, Mirrizzi's syndrome, previous pancreatitis contribute bile duct injuries. Deep dissection on the liver bed in intra hepatic gallbladder and thermal Injury also contribute to bile duct injury in laparoscopic cholecystectomy. Severity of injury was classified according to Dindo et al.⁽¹³⁾ and type of injuries according to Strasberg⁽¹⁴⁾. Apart from a follow-up during the first postoperative months, there were no regular planned visits. Data were analysed by frequency tables and cross tabulation.

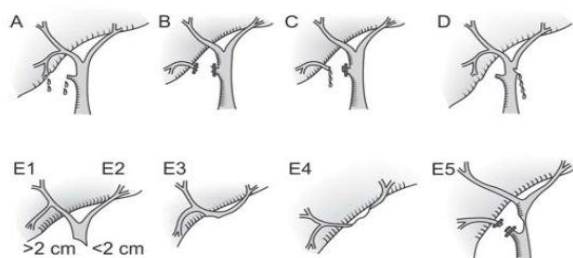
Table 1: General characteristics for 40 patients with bile leaks or bile duct injuries following lap cholecystectomy.

Age(median, range, years)	45	10 – 76
Sex	N	%
Men	12	30
Women	28	70
Risk Factors		
Cholecystitis	9	22.5
Obesity	1	2.5
Previous laparotomy	4	10
Pancreatitis	3	7.5
Bleeding	1	2.5
None	3	4.5
Not stated	19	47.5

Results

During the study period, 40 patients—12 men and 28 women were included in the database. The median age was 45 (range 10–76) years. Incidence data included at NMCH Patna for the period 2013 to 2015. During that period, 40 patients (0.9%) had a bile leak or injury to the bile ducts and 18 patients (0.4%) had an injury to the common bile duct or right hepatic duct. A general overview of patient characteristics is shown in Table 1. Mostly patients were treated at Nalanda Medical College & Hospital Patna, two patients were transferred to other hospital for ERCP and stenting. Median delay from injury to therapy was 5 days (range 0–56 days). In 9 patients (22.5%), the injury was discovered intra operatively, whereas 90% were treated within 3 weeks. Difficult dissection due to previous cholecystitis was stated in 22.5% of the cases. Bile leak was the major symptom in 60% of the patients, whereas 13% had peritonitis or generalized septicaemia. As for injured organ, 21 patients had a leak related to the cystic duct, either a laceration or an imperfect closure of the duct. Six leaks were assumed to be related to aberrant ducts (Luschka's ducts), although this was difficult to prove. In 15 patients, there was an injury to the common bile duct, including the right hepatic or a right segmental duct (Table 2). When the common bile duct was injured, 14 appeared as leaks or peritonitis, whereas 6 had signs of obstruction. Severity of injury was classified according to Clavien–Dindo. Of the injuries, 39% were classified as III a, 45% as IIIb, 10% as IV,

and 6% as V. Follow-up for patients surviving the postoperative period was 3 months to 11 one years (median 6 months).



Figs 1A to E5: Classification of laparoscopic injuries to the biliary tract²

Table 2: Classification of bile duct injuries in 40 patients according to Strasberg (14).

	N	%
A: Cystic or aberrant ducts	21	52.5%
C: Aberrant duct without continuity with the common bile duct	4	10
D: Lateral damage extrahepatic duct	2	5
E2: Common bile duct <2 cm from hepatic confluence	10	25
E3: Hepatic confluence	2	5
E4: Division of right or left hepatic duct.	1	2.5

Table 3: Therapeutic procedures in 40 patients undergoing bile duct injuries / leaks following cholecystectomy.

	Common bile ducts		Cystic duct / aberrant ducts	
	Frequency	%	Frequency	%
Hepaticojejunostomy	4	21	0	0
Suturing of cystic / aberrant / common duct	3	14.28	4	19
Removed clips / drain	2	10.5	0	0
T – tube	5	26.32	2	9.5
Intraabdominal drain	1	5.28	4	19
Intraabdominal drain + stent	3	14.28	8	38
Stent	1	5.26	2	9.5
Antibiotics only	0	0	1	4.7
Total	19	-	21	-

Table 3 shows reoperative procedures by injured organs. Of the 21 patients with cystic duct problems or procedures and/or percutaneous drainage, where as 8 patients had to undergo a pen procedure with closure of the cystic duct or T-tube drainage. In two of these, severe general peritonitis was the indication for operative treatment. In three patients, we found common bile duct stones that were subsequently removed by endoscopic retrograde cholangiography (ERCP) and probably were partially responsible for leakage from the cystic duct. Now mostly patients with cystic duct problems were treated endoscopically.

Of the 19 patients with damage to the common bile ducts, 4 patients (21%) had hepaticojejunostomies (Table 3). For the whole patient series, we found that 28 out of 40 patients (70%) had no postoperative problems or sequelae. In patients treated with hepaticojejunostomies, 2.5% developed a stricture later on (Table 4). One patient died following their bile duct injuries, septicaemia and lung infection complications. 6 patients developed wound infections and were treated with suitable antibiotics. One patient developed leaks following hepaticojejunostomy which was treated conservatively. Leaks was sealed spontaneously in two weeks. One patient developed septicaemia which was treated with higher antibiotics. The last patient was a 44-year-old woman with an imperfect closure of the cystic duct. Due to postoperative leak and peritonitis she underwent an open operation and closure of the duct.

Table 4: Outcome following treatment of bile duct leakage / injuries in 67 patients.

	All Patients		Hepaticojejunostomy	
	Frequency	%	Frequency	%
Uncomplicated	28	70	1	25
Wound Infection	6	15	1	25
Stricture	1	2.5	0	0
Septicaemia	2	5	1	25
Leakage	2	5	1	25
Death	1	2.5	0	0

Discussion

The main findings in this study were that more than 50% of bile duct injuries or leaks following cholecystectomy were related to the cystic duct or assumed aberrant bile ducts in the liver bed of the gall bladder. This is in the same order as was found in an extensive American study comprising 83,000 patients where about 60% of the leaks were related to the cystic duct⁽⁵⁾. As many as 12% of the operations in our series were open cholecystectomies and another 15% were conversions from laparoscopic to open surgery. The reason for this might be that the hospitals have a rather conservative attitude toward recommending operative treatment for gall bladder stones as well as acute cholecystitis. As a

consequence, more patients have gallbladders considered difficult to removed uringlaparoscopic surgery. In addition, most of the open procedures were performed in the first years of the study period. The reported frequency of bile duct injuries varies considerably in published studies (3,4,15). Retrospective studies might contain selection bias, thereby giving a too low incidence of injuries. In a prospective Swedish registry, the frequency of bile duct injuries was reported to be 1.5% which is much higher than the usually stated frequency of 0.2%–0.9% (16). In our series, we found a frequency of 0.4% injuries of the main bile duct and 0.9% when cystic duct problems and aberrant ducts are included.

Risk factors for bile duct injuries (BDIs) are assumed to be related to age, sex, acute cholecystitis, and impacted gallstone within the Hartmann's pouch. Anomalies and anatomical variations of biliary ducts or vascular system are not uncommon and represent operative challenges and looming sources for operative complications. In our series, chronic cholecystitis and previous laparotomy with adhesions were the most commonly reported postoperative problems encountered. In our series IOC was not performed as laparoscopic exploration of CBD was not possible in NMCH. IOC is laso not much helpful in preventing bile duct injuries as more than 50% injuries related tocystic duct. The conclusions of the published studies related to IOC are also conflicting, as only half of them show a benefit from IOC. Iatrogenic injuries to the common hepatic duct or right hepatic duct with side branches are normally severe requiring operative management. Following complete division of the common bile duct, there are mainly two options for repair: direct anastomosis between the cut ends or hepaticojejunostomy with a Roux-Y limb. Most authors consider the last option as the most appropriate method (10,19). This was also the main policy at our department. The outcome after hepaticojejunostomy is generally fair, with strictures as the most severe long-term challenge. Following systematic literature search, it has been

concluded that there is only limited evidence from clinical studies to support specific recommendations as for treatment of bile duct injuries (15). As for primary versus late repair of injuries, this has been a topic of different opinions. Some recommend repair as soon as possible, whereas others advocate a "wait and see" approach for up to 3 months in order to obtain dilatation of the bile ducts, thereby being able to make an anastomosis more easily (20,21). Recurrent cholangitis as a consequence of postoperative strictures is commonly found following surgical repair of the common bile ducts (22). In addition to a well-timed planned preparation, there might be several reasons for the development of strictures, like technical failures during reconstruction, unawareness of constrained blood supply, or extensive damage making anastomoses difficult. Treatment of postoperative strictures should also be individualized, and balloon dilatation might be a good option for many patients (23). The consequences of a major bile duct injury might be severe and may alter a patient's perceived quality of life (24). In general, it is found that the long-term quality of life is reduced following bile duct injuries compared to all patients undergoing laparoscopic cholecystectomy (25). In a study from Poland, Jablonska et al. (26) found that quality of life was better in patients undergoing end-to-end anastomoses compared to hepaticojejunostomies. As four of our patients in this small series died in the course of bile duct injuries, this should focus on the severity of these lesions. This is especially relevant in elderly patients who will tolerate postoperative sepsis and reoperations badly. It is important to act immediately when bile leaks occur. Whether drainage should be performed percutaneously or endoscopically is, however, still debated (11,27). In our series, most patients could be treated with endoscopic procedures, which was also the conclusion in a paper by Pittet al. (28). In conclusion, bile duct injuries are relatively uncommon following laparoscopic cholecystectomy. About 50% of the injuries are related to the common bile duct, and these should be centralized

to hospitals familiar with major hepatobiliary surgery. Strictures following hepatojejunostomies are still a major concern.

Conclusion

Bile duct injuries have cast a shadow of apprehension on other wise wonderful procedure of laparoscopic cholecystectomy. Millions have benefitted from this procedure against gall bladder diseases. Operating surgeons should be aware of factors responsible for bile duct injuries. Strict adherence to the principles of dissection and identifying anomaly bile duct injuries can minimised and outcome following bile duct injuries is good when you are identifying injury during operation. Early recognition of bile duct injury after operation and repair then the outcome is good.

References

1. McKinley SK, Brunt LM, Schwaitzberg SD: Prevention of bile duct injury: The case for incorporating educational theories of expertise. *Surg Endosc* 2014;28:3385–3391 (PMID: 24939158).
2. Strasberg SM, Hertl M, Soper NJ: An analysis of the problem of biliary injury during laparoscopic cholecystectomy. *J m Coll Surg* 1995;180(1):101–125 (PMID: 8000648).
3. Waage A, Nilsson M: Iatrogenic bile duct injury: A population-based study of 152 776 cholecystectomies in the wedish Inpatient Registry. *Arch Surg* 2006;141 (12):1207–1213 (PMID:17178963).
4. Karvonen J, Salminen P, Gronroos JM: Bile duct injuries dur-ing open and laparoscopic cholecystectomy in the laparoscopicera: Alarming trends. *Surg Endosc* 2011;25(9):2906–2910 (PMID:21432006).
5. Chuang KI, Corley D, Postlethwaite DA et al: Does increase experience with laparoscopic cholecystectomy yield more complex bile duct injuries? *Am J Surg* 2012;203(4):480–487(PMID: 22326050)
6. Harboe KM, Bardram L: Nationwide quality improvement of cholecystectomy: Results from a national database. *Int J Qual Health Care* 2011;23(5):565–573 (PMID: 21727152).\
7. Harboe KM, Bardram L: The quality of cholecystectomy in Denmark: Outcome and risk factors for 20,307 patients from the national database. *Surg Endosc* 2011;25(5):1630–1641 (PMID:21136118).
8. Andersson R, Eriksson K, Blind PJ et al: Iatrogenic bile duct injury—A cost analysis. *HPB* 2008;10(6):416–419 (PMID:19088927; PMCID: 2597315).
9. Scurr JR, Brigstocke JR, Shields DA et al: Medicolegal claims following laparoscopic cholecystectomy in the UK and Ireland. *Ann R Coll Surg Engl* 2010;92(4):286–291 (PMID: 20501014;PMCID: 3025217).
10. Holte K, Bardram L, Wettergren A et al: Rekonstruktion af dybe galdevejslesioner efter laparoskopisk kolecystektomi [Reconstruction of major bile duct injuries after laparoscopic cholecystectomy]. *Ugeskr Laeg* 2010;172(9):705 (PMID: 20402019).
11. Pioche M, Ponchon T: Management of bile duct leaks. *J Visc Surg* 2013;150(3 Suppl.):S33–158 (PMID: 23791984).
12. Walsh RM, Henderson JM, Vogt DP et al: Long-term outcome of biliary reconstruction for bile duct injuries from laparoscopic cholecystectomies. *Surgery* 2007;142(4):450–456;discussion 456–457 (PMID: 17950335).
13. Dindo D, Demartines N, Clavien PA: Classification of surgical complications: A new proposal with evaluation in a cohort of 6336 patients and results of a survey. *Ann Surg* 2004;240(2):205–213 (PMID: 15273542; PMCID: 1360123).
14. Strasberg SM: Avoidance of biliary injury during laparoscopic cholecystectomy. *J*

- Hepatobiliary Pancreat Surg
2002;9(5):543–547 (PMID: 12541037).
15. Eikermann M, Siegel R, Broeders I et al: Prevention and treatment of bile duct injuries during laparoscopic cholecystectomy: The clinical practice guidelines of the European Association for Endoscopic Surgery (EAES). *Surg Endosc* 2012;26(11): 3003–3039 (PMID: 23052493).
 16. Tornqvist B, Stromberg C, Persson G et al: Effect of intended intraoperative cholangiography and early detection of bile duct injury on survival after cholecystectomy: Population based cohort study. *BMJ* 2012;345:e6457 (PMID: 23060654; PMCID: 3469410).
 17. Ford JA, Soop M, Du J et al: Systematic review of intraoperative cholangiography in cholecystectomy. *Br J Surg* 2012;99(2):160–167 (PMID: 22183717).
 18. Ludwig K, Bernhardt J, Steffen H et al: Contribution of intraoperative cholangiography to incidence and outcome of common bile duct injuries during laparoscopic cholecystectomy. *Surg Endosc* 2002;16(7):1098–1104 (PMID: 12165830).
 19. Fathy O, Wahab MA, Hamdy E et al: Post-cholecystectomy biliary injuries: One center experience. *Hepatogastroenterology* 2011;58(107–108):719–724 (PMID: 21830376).
 20. Iannelli A, Paineau J, Hamy A et al: Primary versus delayed repair for bile duct injuries sustained during cholecystectomy: Results of a survey of the Association Francaise de Chirurgie. *HPB* 2013;15(8): 611–616 (PMID: 23458568; PMCID: 3731582).
 21. De Reuver PR, Grossmann I, Busch OR et al: Referral pattern and timing of repair are risk factors for complications after reconstructive surgery for bile duct injury. *Ann Surg* 2007;245(5):763–770 (PMID: 17457169; PMCID: 1877064).
 22. Bauer TW, Morris JB, Lowenstein A et al: The consequences of a major bile duct injury during laparoscopic cholecystectomy. *J Gastrointest Surg* 1998;2(1):61–66 (PMID: 9841969).
 23. Varabei A, Arlouski Y, Vizhinis E et al: The use of double balloon enteroscopy for diagnosis and treatment of strictures of hepaticojejunal anastomoses after primary correction of bile duct injuries. *Wideochir Inne Tech Malo Inwazyjne* 2014;9(2):219–225 (PMID: 25097690; PMCID: 4105680).
 24. Melton GB, Lillemo KD, Cameron JL et al: Major bile duct injuries associated with laparoscopic cholecystectomy: Effect of surgical repair on quality of life. *Ann Surg* 2002;235(6):888–895 (PMID: 12035047; PMCID: 1422520).
 25. Landman MP, Feurer ID, Moore DE et al: The long-term effect of bile duct injuries on health-related quality of life: A metaanalysis. *HPB* 2013;15(4):252–259 (PMID: 23458623; PMCID: 3608978).
 26. Jablonska B, Olakowski M, Lampe P et al: Quality-of-life assessment in the treatment of iatrogenic bile duct injuries: Hepaticojejunostomy versus end-to-end biliary reconstructions. *ANZ J Surg* 2012;82(12):923–927 (PMID: 22931473).
 27. Baillie J: Endoscopic approach to the patient with bile duct injury. *Gastrointest Endosc Clin N Am* 2013;23(2):461–472 (PMID: 23540970).
 28. Pitt HA, Sherman S, Johnson MS et al: Improved outcomes of bile duct injuries in the 21st century. *Ann Surg* 2013;258(3): 490–499 (PMID: 24022441).