



Harlequin Ichthyosis: Case Report of a rare disorder and Stigma attached to it

Author

Dr Manju Lata Sharma

Surveillance Medical Officer WHO Country Office India unit Bikaner & Ex Consultant Paediatrician and Neonatologist M.N. Hospital and Research Centre Bikaner

Corresponding Author

Dr Manju Lata Sharma

Abstract

Background: Disorders of cornification (ichthyoses) are a group of inherited disorders characterised clinically by extensive scaling and histopathologically by hyperkeratosis. These disorders can cause considerable disfigurement in the newborn and may be associated with complications like electrolyte imbalance, sepsis, meningitis, dehydration and respiratory distress. Moreover these disorders may cause considerable psychological trauma to mother and other caregivers owing to the disfigurement of the affected newborn. In some communities there is considerable social stigma attached to it. The newborn babies having ichthyosis have mortality rates ranging between 10-40%. Harlequin ichthyosis (HI) is a severe form of congenital ichthyosis with an autosomal recessive pattern. The incidence is very rare and reported to be nearly 1 in 3,00,000 live births. HI classically presents with severe keratinised and alligator-like skin. HI has been linked to various genetic mutations most common of which is ABCA 12.

Case Report: A 7 day old female child was brought to our community centre in view of abnormal appearance of the skin and inability to take proper feeding since birth. Birth history revealed that the baby was full term (37 weeks), delivered vaginally at home 7 days back. Baby cried immediately after birth. Parents noticed abnormal appearance of the baby at birth but baby was not taken to any hospital. On day 7 of birth baby was brought to our community centre. On examination there were thick armor-like plates covering the whole body with intervening deep-red fissures causing oozing of blood from the fissures. Ectropion, eclabium, flattening of ears and nose were also noted. There was considerable disfigurement of facial features. bullous skin lesions were seen on major joints including knees, elbows and ankles. All natural orifices were patent. Other vital parameters were normal. Parents were counselled regarding need for NICU admission of the baby. But parents refused admission despite extensive counselling.

Conclusion: Harlequin Ichthyosis is the rarest form of ichthyosis. Despite awareness about this group of disorders there is considerable stigma attached to it. In some developing countries children with ichthyosis are called "snake children". Concern about their social inclusion because of beliefs related to the clinical appearance may be the reason behind parents' refusal to take medical assistance as was the case in our patient.

Keywords: Harlequin ichthyosis, Autosomal Recessive, ABCA 12, Social stigma.

Introduction

Disorders of cornification (ichthyoses) are a group of rare inherited disorders characterised by the presence of excessive amounts of dry surface scales. It is a disorder of keratinisation or cornification^[1]. Abnormal epidermal differentiation or metabolism is the basic pathology in these disorders. Histopathological examination of skin biopsy will show hyperkeratosis in these neonates. Harlequin ichthyosis (HI) is the most severe and rare form of congenital ichthyosis^[2]. The mode of inheritance is usually autosomal recessive. The characteristic feature of HI is thickening of keratin layer in the skin of newborn. The characteristic appearance of skin is sometimes called “armor plating” or “alligator-skin”^[3]. There are associated abnormalities of the eyes, ears, mouth (eclabium) and severely disfigured face. The mouth of the newborn baby is pulled open due to taut skin. Ocular abnormalities associated with HI include eclabium, ectropion, strabismus and exposure keratitis^[4]. The ears usually are poorly developed and in severe cases may be absent. Flexion contractures of arms and legs is frequently seen secondary to overstretched skin. The skin is denuded which may cause fluid loss leading to dehydration, electrolyte imbalance and bacterial colonisation causing sepsis^[5].

Mode of transmission is autosomal recessive and underlying genetic defect lies in lipid-transporter gene ABCA12 on chromosome 2. Since the disease causes considerable amount of disfigurement it may cause profound psychological trauma in parents or other caregivers. Children who survive post-infancy may face stigmatisation and discrimination owing to abnormal appearance of skin. The children are often referred to as “snake children” owing to excessive scaling. The parents are caregivers usually delay in consulting paediatrician fearing ostracism and discrimination^[6].

We present here a case of 7 day old female child who was brought to our community centre in view of abnormal appearance of the face and body. Characteristic features prompted an immediate

diagnosis of harlequin ichthyosis and immediate NICU admission was advised. Parents refused admission despite extensive counselling.

Case Report

A 7 day old female child was brought to our community centre with the complaints of abnormal facial features and difficulty in accepting feeds owing to abnormal mouth. There was no history of consanguinity. Antenatal history was non-significant. No antenatal ultrasound was done. Baby was delivered by normal vaginal delivery at home. Baby cried immediately after birth. Relatives noticed abnormal facial features of the baby but didn't consult any paediatrician fearing stigmatisation. The baby was given direct breast feeding and no top feeding was given. Mother noticed that the baby was unable to take proper feeds due to abnormal shape of mouth. There was also history of thickened skin with fissures and oozing of fluid and blood from these fissures. Eventually on day 7 baby was brought to our community centre for consultation.

Her weight was 2.2 kg. Head circumference was 31cms and total length was 47 cms. On examination the baby had thickened skin and scaling involving whole of the body. Pinna and nose were underdeveloped. There was severe ectropion and eclabium. There were contractures involving hands and feet. There were bullous lesions involving major joints including knees and ankles. Blood was seen oozing from fissures of skin. There was foul smelling discharge from some of the skin lesions suggestive of pyogenic infection. All natural orifices were patent. Cardiovascular examination was normal. Baby appeared lethargic and baby was unable to suck owing to taut facial skin. Respiratory movements appeared feeble owing to tightened skin over chest wall. Characteristic features immediately prompted the diagnosis of Harlequin Ichthyosis (HI). [figure 1]

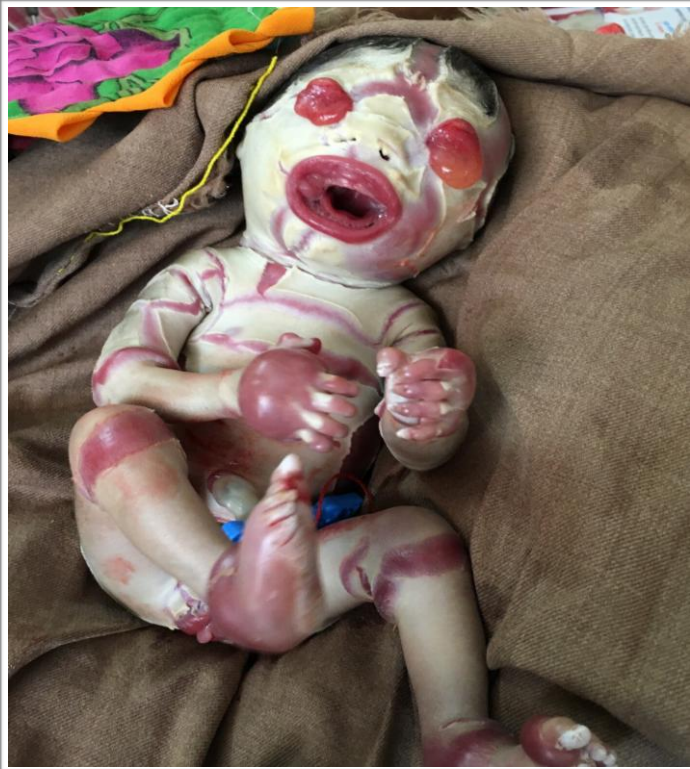


Figure 1 : Harlequin Ichthyosis- Note dry and thickened skin with fissures, Eclabium, hypoplastic nose and pinna, bullous skin lesions over hands and feet.

Parents were informed about the condition and explained in detail about the cause of this disorder. They were further informed about the need for baby to be admitted in NICU. The parents refused admission despite being informed about the risk to life of the baby. Mother appeared depressed on account of appearance of the baby. In view of parents refusal to get the baby admitted in NICU despite extensive counselling baby was prescribed oral antibiotics (Amoxycillin+ potassium cluvalunite) and emollients for local application.

Discussion

Congenital ichthyosis is an inherited disorder of cornification. The usual mode of inheritance is autosomal recessive. Harlequin ichthyosis is the most severe and rare form of congenital ichthyosis with an incidence of 1: 3,00,000 live births. Approximately only 100 cases of HI have been reported worldwide so far in literature [7]. The

mutation responsible for HI is reported to be ABCA12 gene mutation on chromosome 2. This gene is thought to play an important role in the formation of lamellar granules and the discharge of lipids into the intercellular spaces. Defect in this functions may cause the epidermal barrier defect seen in this disorder^[8]. The name harlequin is derived from the dress of harlequin clowns that have diamond like patches similar to skin plaques seen in HI. Earlier these were called harlequin fetus because rarely these children would survive after birth. But with advanced neonatal care facilities there is an increase in survival of these children and the term harlequin fetus is nowadays replaced by Harlequin ichthyosis^[9]. It is characterised by hard, dried skin forming diamond shaped plaques within which multiple fissures are found. This taut skin severely affects the normal features of the neonate. There is considerable distortion of lips (eclabium), eyelids (ectropion), ears (hypoplastic or absent ears) and nostrils^[10].

Other clinical features include facial and cranial deformities. Poorly developed ears and pinna. Nose may be severely flattened or even absent. Ocular features may include ectropion leading to exposure keratitis and strabismus. Skin around the face is taut and may cause fixed and wide grimace. Limbs may show contractures owing to contracted skin. Bullous skin lesions may be seen specially around the large joints. The common complications seen in these babies include dehydration due to fluid loss, anaemia due to blood loss, skin infections and sepsis due to loss of skin barrier, electrolyte imbalance, exposure keratitis due to ectropion, respiratory insufficiency due to taut skin over chest, hypothermia, hypoglycaemia and renal failure^[11].

Since there is no curative treatment of HI and there is considerable psychological trauma to the parents owing to the disfigured appearance of the newborn an antenatal diagnosis is desirable. The condition can be diagnosed in utero by various invasive diagnostic procedures including amniocentesis and chorionic villous sampling^[12].

3D ultrasonography is the non invasive technique which may help in antenatal diagnosis ^[13].

Treatment of HI consist of meticulous NICU care aimed at preventing hypothermia, hypoglycaemia, dehydration and electrolyte imbalance. The babies are usually nursed in humidified incubators. Strict asepsis and nutritional supplementation is essential. Soaking the hardened skin in normal saline is important. emollients are also used to soften the skin. Ophthalmologic consultation is usually required for management of ectropion and exposure keratitis. Artificial tears and local antibiotic ointment may be used in babies who have ectropion. In those babies who survive long term management of contractures is essential which may involve physiotherapy and surgeries. systemic retinoids are essential component of the long term therapy of HI. Retinoids decrease scaling of skin and promote shedding of hyperkeratotic skin.

One important aspect which needs to be addressed in these patients is social stigma and ostracisation of the families having children with ichthyosis. There is widespread misconception about the aetiology of this disorder in the society. In some communities this is believed to be caused due to mothers attraction to the look of crocodile skin, and thus, the children acquired the skin of a reptile ^[14]. In some other cultures (Philippine) they are thought to be due to maternal carvings. Many times the affected children are called “ snake children” and parents face discrimination, ostracism and difficulties of social integration ^[15]. For these reason many a times children having HI are not taken outside home even if they are in need of immediate medical care. Our case is similar case in point where despite explaining everything parents decided against admitting the baby in NICU.

Conclusion

Harlequin ichthyosis is a rare inherited disorder of cornification. Since there is no cure of this condition antenatal diagnosis by chorionic villous sampling or amniocentesis is desirable. In

neonates with HI strict asepsis, thermoregulation and prevention of dehydration is essential. With advances in neonatal care as more and more children with HI are surviving there is a need to address social issues like stigmatisation, discrimination and ostracisation of children with HI and their family members.

Conflict of Interest : None

References

1. Oji V, Tadini G, Akiyama M, Blanchet Bardon C, Bodemer C, Bourrat E. Revised nomenclature and classification of inherited ichthyoses: results of the First Ichthyosis Consensus Conference in Sorèze 2009. *J Am Acad Dermatol*. 2010 Oct. 63(4):607-41.
2. Salehin S, Azizimoghadam A, Abdollahimohammad A, Babaeipour-Divshali M. Harlequin ichthyosis: Case report. *Journal of Research in Medical Sciences : The Official Journal of Isfahan University of Medical Sciences*. 2013;18(11):1004-1005.
3. Arikan II, Harma M, Barut A, Harma MI, Bayar U. Harlequin ichthyosis: A case report and review of literature. *Anatolian J Obstet Gynecol*. 2010;1:1-3.
4. Al-Amry MA. Ocular manifestation of Ichthyosis. *Saudi Journal of Ophthalmology*. 2016;30(1):39-43.
5. Pallavi P. Saple, Md Ashfaque Tinmaswala, Nitin Kumar, Arpita, Sneha W. Congenital Ichthyosis – A Case Report. *International Journal of Medical and Health Sciences*. 2015 Apr 4 (2): 284-286.
6. Kelsell DP, Norgett EE, Unsworth H, et al. Mutations in ABCA12 Underlie the Severe Congenital Skin Disease Harlequin Ichthyosis. *American Journal of Human Genetics*. 2005;76(5):794-803.
7. Martin RJ, Fanaroff AA, Walsh AA. Fanaroff and Martin's neonatal-perinatal

- medicine. 9th ed. United States, St Louis: Elsevier, Mosby 2011; 1713-1714
8. Akiyama M, Sugiyama-Nakagiri Y, Sakai K, et al. Mutations in lipid transporter ABCA12 in harlequin ichthyosis and functional recovery by corrective gene transfer. *Journal of Clinical Investigation*. 2005;115(7):1777-1784.
 9. Mithwani AA, Hashmi A, Shahnawaz S, Al Ghamdi Y. Harlequin ichthyosis: a case report of prolonged survival. *BMJ Case Reports*. 2014;2014:bcr2013200884.
 10. Sandler B, Hashimoto K. Collodion baby and lamellar ichthyosis. *J Cutan Pathol* 1998;25:116–21.
 11. Van Gysel D, Lijnen RLP, Moekti SS, et al. Collodion baby: a follow-up study of 17 cases. *J Eur Acad Dermatol Venereol* 2002;16:472–5
 12. Akiyama M, Kim DK, Main DM, et al. Characteristic morphologic abnormality of harlequin ichthyosis detected in amniotic fluid cells. *J Invest Dermatol* 1994;102:210–13
 13. Alnemer M. Prenatal exclusion of harlequin ichthyosis with 3D ultrasound. *Ultrasound Obstet Gynecol* 2008;32:463.
 14. Korsaga/Somé N, Salissou L, Tapsoba GP, Ouédraogo MS, Traoré F, Doulla M,Barro/Traoré F, Niamba P, Traoré A. [Ichthyosis and social stigma in BurkinaFaso]. *Ann Dermatol Venereol*. 2016 Aug-Sep;143(8-9):554-8.
 15. Abad PJB, Tan ML, Baluyot MMP, et al. Cultural beliefs on disease causation in the Philippines: challenge and implications in genetic counseling. *Journal of Community Genetics*. 2014;5(4):399-407.