



Endoscopic DCR With and without Silicone Stenting- A Comparison of Outcome

Authors

Jitendra Singh Yadav, Jagdish Prasad Purohit, Vineet Kumar, Siva Selvara

Abstract

In the obstruction of nasolacrimal duct in cases of chronic dacryocystitis, various techniques of dacryocystorhinostomy are used for the better result. Endoscopic dacryocystorhinostomy is used widely used nowadays. In some cases recurrence of obstruction occurs due to inflammation and adhesion of nasolacrimal or the canaliculi. Various methods are used to prevent this recurrence like usage of Mitomycin C intra-operatively or placement of silicone stent.

In this study, we have compared the outcomes of endoscopic DCR with and without bicanalicular silicone stenting on 20 cases of chronic dacryocystitis (post saccul obstruction) for each group.

We observed that endoscopic DCR with placement of silicone stent yielded better results than just making the stoma on the lateral wall.

Keywords: Epiphora, Postsaccul obstruction, Endoscopic DCR, Stenting.

Introduction

Chronic dacryocystitis is an inflammatory condition of the lacrimal apparatus mainly the lacrimal sac leading to blockage of tear draining mechanism at different levels ^[1]. It can cause blockage of tear drainage distal to the sac ^[2] (in the nasolacrimal duct- post sac) or proximal to the sac (in the canaliculi - pre sac). The patients will present with symptoms of epiphora, swelling of the lacrimal sac region, pain and continuous or intermittent episodes of purulent discharge from the corresponding eye ^[3]. It is more in elderly women than in comparison to men ^[4].

Dacryocystorhinostomy (DCR) is a surgical procedure used for the treatment of chronic dacryocystitis. In DCR surgery, a stoma is created between medial wall of lacrimal sac and nasal

cavity which will heal and form a fistula which will lead to the continuous drainage of tears into the nasal cavity thus curing the excess watering and stagnation of tears in the sac which caused the infection ^[1]. DCR can be performed by two different approaches viz I- External approach and II- Endoscopic approach. Because of high failure rate and cosmetic importance nowadays Endoscopic DCR is the surgery of choice over the older external approach ^[5]. Mc Donogh and Meiring in 1989 were the first to introduce rigid nasal endoscopy for the lacrimal sac surgery ^[6]. In the dacryocystorhinostomy, reports suggest that endoscopic approach is more successful with success rates ranging from 82% to 95% as compared to external approach dacryocystorhinostomy ^[7]. Placement of silicone stent

intraoperatively through both the canaliculi is having multiple schools of thought- in patient selection, duration of placement of the stent and outcome. Silicon stent is placed in cases of canalicular obstructions for preventions of re-obstruction by granulation and adhesion formation. In our study Endoscopic DCR with bicanalicular silicone stent placement is compared to Endoscopic DCR without stenting in the patients who were not responding to medical management for dacryocystitis^[8].

Methods and Material

This was a prospective study done on 20 cases of Chronic dacryocystitis who came to ENT department of MLB medical college, Jhansi (UP), India from July 2012 to June 2016 and underwent Endoscopic DCR with bicanalicular silicone stenting. These cases were compared to 20 control patients who underwent Endoscopic DCR without silicone stenting.

Inclusion Criteria

1. All cases of chronic dacryocystitis presenting to OPD consenting to undergo the study
2. All cases admitted to ward willing for surgery
3. All cases with postsac obstruction

Exclusion Criteria

1. Cases not consenting for the study upon them
2. Cases not willing for surgery
3. Cases with presacal canalicular obstruction
4. Patients with atrophic rhinitis

All the patients were admitted and complete history taking and clinical examination were done. Examination was done by palpation of lacrimal fossa to look for enlarged lacrimal sac, tenderness and mucoid and mucopurulent reflux through the puncta. Clinically the level of obstruction of the lacrimal apparatus was identified by syringing of the system through the puncta. CT paranasal sinus

and X ray PNS (Water's view) to rule out rhinosinusitis, deviated nasal septum, polyposis were done. Patients with only post-sacal obstruction were selected for the study. After the provisional diagnosis was done, patients were operated by endoscopic DCR. 20 control cases were taken retrospectively who had undergone Endoscopic DCR without stenting. The cases selected for the study underwent Endoscopic DCR with stenting through the upper and lower canaliculi. No Mitomycin-C local instillation during surgery was done in any of the cases.

Before starting the surgery procedure, the nasal cavity was packed with cotton pledgets soaked in 4% lignocaine mixed adrenaline (1:3000) in 5:1 ratio for topical anesthesia. This also helps in vasoconstriction and less blood loss during surgery thus giving clear field of vision intra-operatively. In the lateral wall of nose, anterior to the attachment of middle turbinate, local anaesthetic agent is infiltrated for local anaesthesia as well as hydro-dissection of the tissue. For proper visualization of the field, at the time of surgery rigid 0 degree and 30 degree endoscopes were used. Anterior end of middle turbinate is identified a vertical incision is made. Mucosal flap is elevated over the frontal process of maxilla thus exposing the lacrimal crest and lacrimal bone. The junction of lacrimal bone and crest was identified and it corresponds to the underlying nasolacrimal duct (NLD). The bone is removed by bone punch and the NLD is opened. The NLD is traced superiorly and laterally to identify the lacrimal sac. The anatomy is confirmed by intra-operatively pressing over the eye ball which will make the sac bulge into the nasal cavity once the bone is removed. In some cases the bone is removed with the help of electric drill using a diamond burr. A surgical opening is made in the lacrimal sac and the content will gush into the nasal cavity (Figure - 1). The puncta were dilated from outside and syringing was done with saline mixed with steroids like dexamethasone to avoid stricture. A silicone bicanalicular stent was introduced from both the puncta and the inferior

free ends were brought out through the nasal cavity (Figure – 2 and 3). This stent was kept for a period of 6 weeks and then removed. Post-operatively regular syringing of the puncta and nasal wash were done. Post-operative results were noted and followed up for a period of 6 months and the results were compared. Outcome is considered as failure whenever the patients were not relieved of the symptoms.

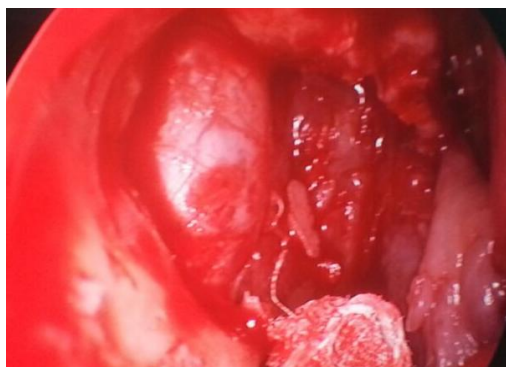


Figure – 1 showing stoma made between lateral wall and lacrimal sac.

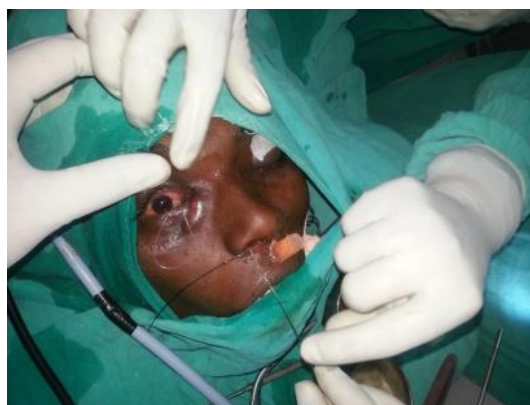


Figure – 2 showing introduction of silicone stent through the upper and lower puncta.

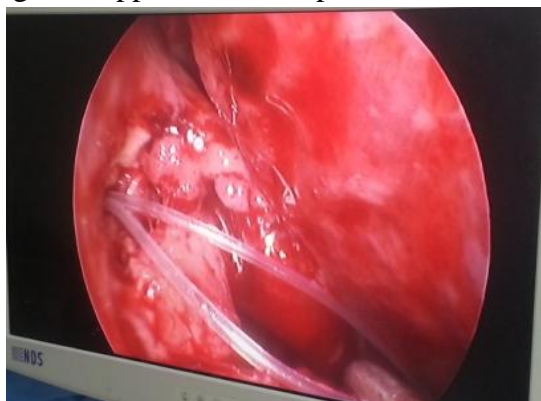

Figure – 3 showing the lower ends of stent brought into the nasal cavity through the stoma made.

Observation

In our study, 40 patients of chronic dacryocystitis were selected- 20 cases and 20 controls. Patients were under the age group of 20 to 60 years. Male to female patient ratio was 3:7 showing that the condition is more common in females. In 40 patients endoscopic DCR without stenting was done in 20 patients (Control group) and endoscopic DCR with stenting was done in 20 cases (Case group).

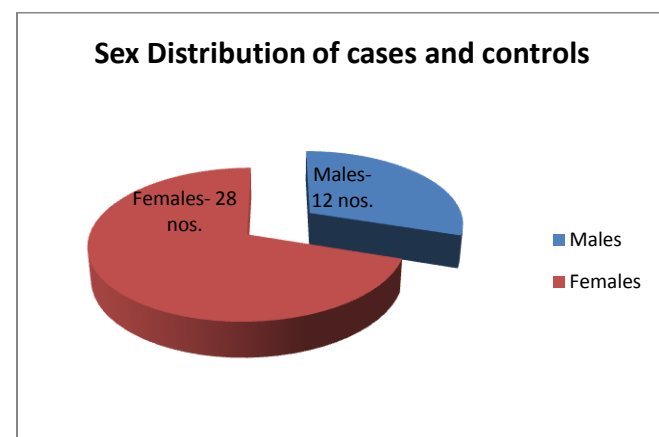


Figure - 1 shows the sex distribution among the study population

The outcome of the cases and controls have been noted and tabulated in the following table.

No.	Surgery done	Success	Failure	Percentage of success rate
20 cases	Endoscopic DCR with stenting	20	0	100%
20 controls	Endoscopic DCR without stenting	16	4	80%

From the above data it is found that the technique of Endoscopic DCR with bicanalicular silicone stenting is having 100% success rate compared to cases without silicone stenting.

Discussion

In our study, out of the total 40 patients studied, only twelve were males and the remaining 28 were females. This gender disparity in the incidence of chronic dacryocystitis has been reported in the past by other scholars also. The reason for higher incidence of chronic dacryocystitis in Indian females can be because of common usage of kajal for cosmetic purpose.

Higher incidence of the disease was noted in lower socioeconomic status in our study. This fact is because of prolonged exposure of Indian lower socioeconomic status ladies to smoke while cooking with firewood fuelled stoves.

Coming to the success rate of Endoscopic DCR with and without bicanalicular stenting, all the cases (20; 100%) were relieved of their symptoms post-operatively in cases of Endoscopic DCR where silicone bicanalicular stent was placed. But in cases where the stent was not placed, the success rate drastically decreased to 80% (4 patients had recurrent symptoms within a period of 6 months of surgery).

In endoscopic DCR without stenting the symptoms is recurring because of closure of stoma created between the lateral wall of nose and lacrimal sac. This can happen because of reasons like formation of granulation around the stoma, fibrosis of the canaliculi due to intra-operative trauma, formation of synechiae between the lateral wall and nasal septum, undiagnosed cases of atrophic rhinitis etc. In cases where the stent has been placed intra-operatively, the patency of the lacrimal apparatus is maintained even in post-operative. The lower ends of the sterile silicone stent placed into the apparatus through the upper and lower puncta were brought out of the nasal cavity and their ends were tied. The pores present in the ocular end of the stent will allow the continuous drainage of the tears even when the stent is in place. Patency is also maintained by the pumping action of tears by the regular contraction of the Orbicularis oculi muscle while blinking of the eyes.

The stent was kept in place for 6 weeks. This time allows all the raw surfaces in the surgical site to heal. Hence the remote chance of synechiae formation is ruled out by this technique giving 100% success rate in this procedure.

Conclusion

Our study concludes that bicanilicular silicone stenting in Endoscopic DCR surgery for cases of

chronic dacryocystitis with nasolacrimal duct blockade is more beneficial and gives less post-operative morbidity thus increasing the success rate of Endoscopic DCR than Endoscopic DCR without stenting.

References

1. Glen Cambell MD, The treatment of chronic dacryocystitis from the viewpoint of ophthalmologist; Can Med Assoc Journal: 1929 Dec; 670-674.
2. Faden HS. Dacryocystitis in children. Clin Pediatr (Phila) 2006; 45(6):567–569.
3. Ashley Brissette, Kelly Schweitzer et al. Can you identify this condition? Can Family Physician. 2011Jan; 57(1): 58-59.
4. B Badhu, S Dulal et al. Epidemiology of Chronic Dacryocystitis and Success Rate of External Dacryocystorhinostomy in Nepal; July 2009: Pg 79-82.
5. Welham RA, Henderson PH. Results of dacryocystorhinostomy. Analysis of causes for failures. Trans Ophthalmol Soc UK. 1973; 93:601–9.
6. McDonogh M, Meiring JH, Endoscopic transnasal dacryocystorhinostomy; J Laryngol Otol: 1989 June; 103(6): 585-587.
7. Madge SN, Chan W et al. Endoscopic dacryocystorhinostomy in acute dacryocystitis: A multicenter case series; Orbit. 2011 Jan; 30(1):1-6.
8. Sudhir M. Naik, Mohan K. Appaji et al. Endonasal DCR with Silicon Tube Stents: A Better Management for Acute Lacrimal Abscesses; Indian J Otolaryngol Head Neck Surg. 2013 Aug; 65(Suppl 2): 343–349.