

**Original Article****Relation of Optic Nerve to the Posterior Ethmoidal and Sphenoidal Sinuses; CT Study in Western Region of Nepal**

Authors

Dr Sarbada Makaju¹, Dr Prakash Sharma², Dr B.P Powar³¹Department of Anatomy, Manipal College of Medical Sciences, Pokhara, NepalEmail: sarbada@hotmail.com, sarbadamakaju@gmail.com²Manipal Teaching Hospital, Pokhara, Nepal³Manipal College of Medical Sciences, Pokhara NepalEmail: drbhawani09@gmail.com**Abstract**

In the human beings there are four pairs of para-nasal sinuses. Among these sinuses, sphenoidal sinuses are the second largest. The sinuses play important role in the human beings. The relations of all the sinuses are very important. The coronal CT scan is used for my researches. The study is done in Nepalese population. All the data were collected from Manipal Teaching hospital, Pokhara, Nepal. This study shows Type 1- 60%, Type 2- 38% and Type 3- 3% in the right side. Whereas in the left side also Type 1- 68%, Type 2- 29% and Type 3- 3%. According to the range, Range 2 is having the maximum number of Type 1 sphenoidal sinus in right and left side. Over all the most common types of sphenoidal sinus is type-1 in both sides. When we compare with gender, in the both gender also type-1 is the most common. The aim of this study was to determine the different types of sphenoidal sinus and its clinical importance.

Introduction

The human skull consists of the paired para-nasal sinuses. The main function of the para-nasal sinuses is to lighten the skull. Among all the para-nasal sinuses, the sphenoidal sinus is considered as second largest para-nasal sinuses in human beings. The sphenoidal sinus is located within the body of sphenoid. The relations of sinuses plays very important role during surgery. Out of this, the relations of the sphenoidal sinus plays crucial role during surgery. Therefore otolaryngologist should have the sound knowledge of anatomic relationships of both posterior ethmoidal sinus and sphenoidal sinus. The optic nerve is the close relation of the sphenoidal sinus.¹

The optic nerve passes through the optic canal and forms a chiasm in the pre-chiasmatic part of the body of sphenoid. According to the accessible, the sphenoid sinus is the most inaccessible paranasal sinus which is enclosed within the body of sphenoid bone.²

The sphenoidal sinus opens into the supreme meatus in the lateral wall of nasal cavity. Due to extensive pneumatization of sphenoidal sinus and bony dehiscence leads to the complication of optic nerve injury.³

Nasal endoscopic is used to view the condition of the sinuses. The use of functional endoscopic sinus has been used for surgical procedures since 1984. During the endoscopic surgery, there is

an increase in the frequency of serious complications. Among the complication, death is the serious complication leading to intracranial and orbital injuries. Therefore the clear vision of relationship of sphenoidal sinuses and the course of the optic nerve is really critical while performing the surgery of paranasal sinuses. The success of the endoscopic depends upon the adequate knowledge of anatomy and relations of it.

According to some researches the optic nerve occasionally passes through the sphenoidal sinus. The shape of the sphenoidal sinuses are irregular with pneumatization varies from absent to extensive.⁵

The sphenoidal sinuses forms the roof of the nasal cavity. Among the advance technique, CT scan is used to view the proper relation of the optic nerve with sphenoidal sinuses. In both the axial and coronal view, the relation of optic is seen properly but out of this coronal is the best to view the relations of it.⁶ Some authors came with the result that the relation of the optic nerve with the sphenoidal sinuses varies according to the ethnicity.⁷ Embryologically, at the age of 8–10 years, the cavity in the sphenoidal sinus is visible but the definitive cavity will be formed at age of puberty.⁸

Materials and Methods

Types of study: Retrospective

Sample size: 100 coronal sections of CT scan

Time periods- 1-2 years

The entire samples were collected in the Department of Radiology, Manipal Teaching Hospital.

Methods: Based on DeLano et al. (1996)⁹ it has been classified into four types

Type 1-

The nerve is located in superior-lateral of sphenoidal sinus without any indentation in the sphenoidal and ethmoidal sinuses

Type 2-

The nerve indents the sphenoid sinus without contacting the posterior ethmoid cells.

Type 3-

The nerve runs through the sphenoid sinus and it is surrounded by the pneumatized sinus for at least 50%

Type 4-

The nerve courses close to both the sphenoid sinus and posterior ethmoid sinus

Exclusion and inclusion Criteria:

Exclusion

- Below the age -14 in case of female
- Below the age -15 in case of male

Inclusion

- Above the age - 14 in case of female
- Above the age – 15 in case of male.

Objectives of the study

To rule out the relations and variation of optic nerve in relation to the sphenoidal and posterior ethmoidal sinuses.

Statistic Analysis

SPSS 21

Results

Table 1 According to range, showing the types of sphenoidal sinus in right side

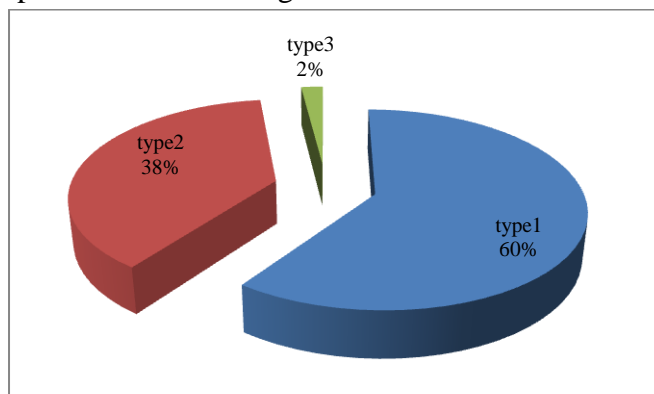
	type_right side			Total	P-value
	type1	type2	type3		
1.00	14	7	0	21	0.5
2.00	21	18	0	39	
3.00	11	7	1	19	
4.00	10	3	1	14	
5.00	4	3	0	7	

The table showing the types of sphenoidal sinus in right is significant.

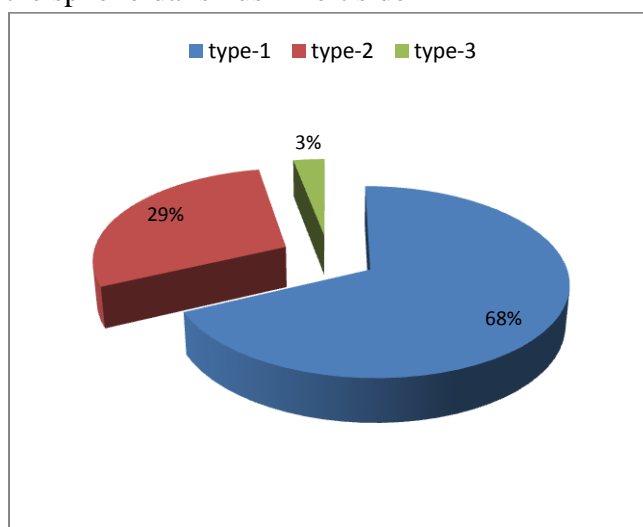
Table 2 According to range, showing the types of sphenoidal sinus in left side

	type_left			Total	P-Valve
	type1	type2	type3		
1.00	14	7	0	21	0.58
2.00	26	11	2	39	
3.00	13	6	0	19	
4.00	8	5	1	14	
5.00	7	0	0	7	

Above table is showing the types of the sphenoidal sinus of left side which is insignificant.

Chart 1 Showing the percentage of the types of sphenoidal sinus in right side

The most common type of sphenoidal sinus is Type-1 in right side.

Chart 2 Showing the percentage of the types of the sphenoidal sinus in left side

In the left side also the most common type of sphenoidal sinus is type-1.

Table 3 Showing the types of sphenoidal in the right side according to the gender

		type_right			Total	P-Valve
		type1	type2	type3		
sex	female	39	20	0	59	0.11
	male	21	18	2	41	
Total		60	38	2	100	

The most common type of sphenoidal sinus is Type-1 in both the gender. It is statically significant.

Table 4 Showing the types of sphenoidal in the left side according to the gender

		type_left			Total	P-Valve
		type1	type2	type3		
sex	female	42	15	2	59	0.63
	male	26	14	1	41	
Total		68	29	3	100	

The most common type of sphenoidal sinus is Type-1 in both the gender.

Table 5 Showing the only type 1 in both side.e right and left

		Only type 1 both side		Total (n=100)	P- Valve
		Absence of type1 in both side	Presence of type 1 in both side		
sex	female	32	27	59	0.85
	male	23	18	41	

The presence of Type-1 in both side is 27 and 18 respectively. It is statically insignificant.

Table 6 Showing the only type-2 in both side

		Only type-2 in both side		Total n-100	P valve
		type2	Absence of type-2		
sex	female	4	55	59	.013
	male	10	31	41	

The presence of Type-2 in both side is 4 and 10 respectively. It is statically significant

Table 7 According to the range Showing only the type-1 in both side

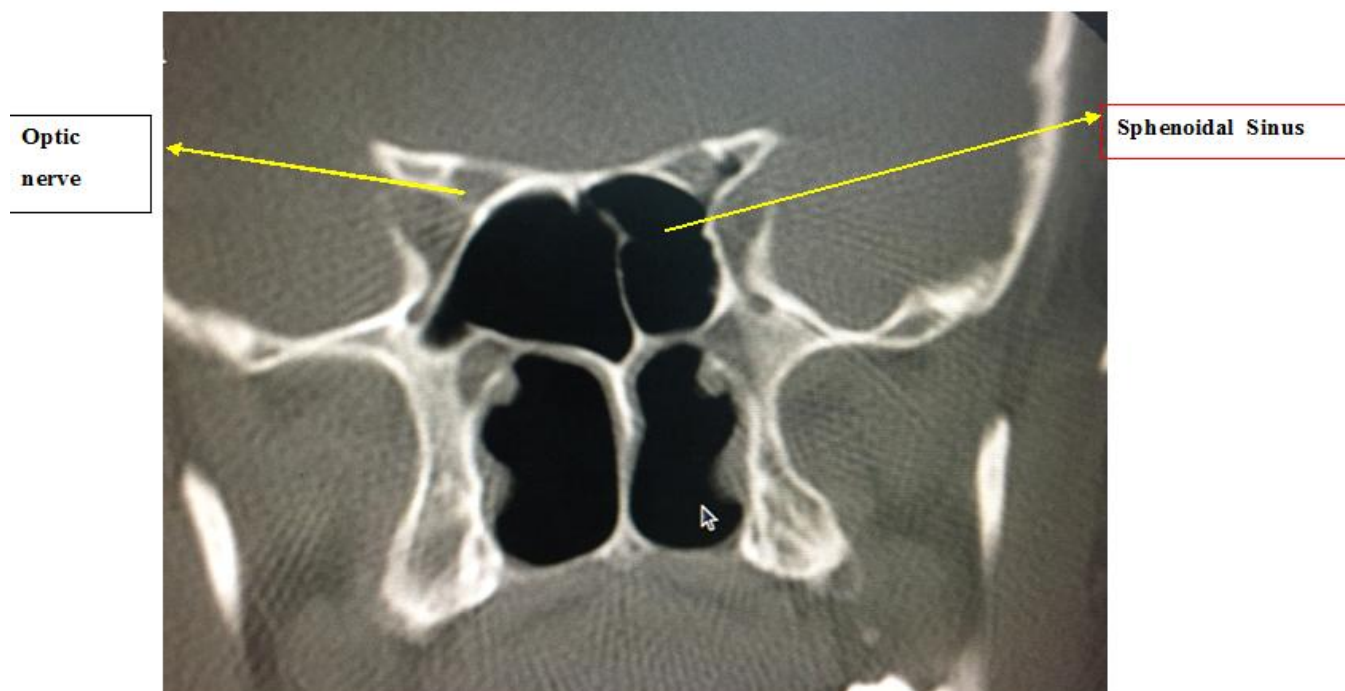
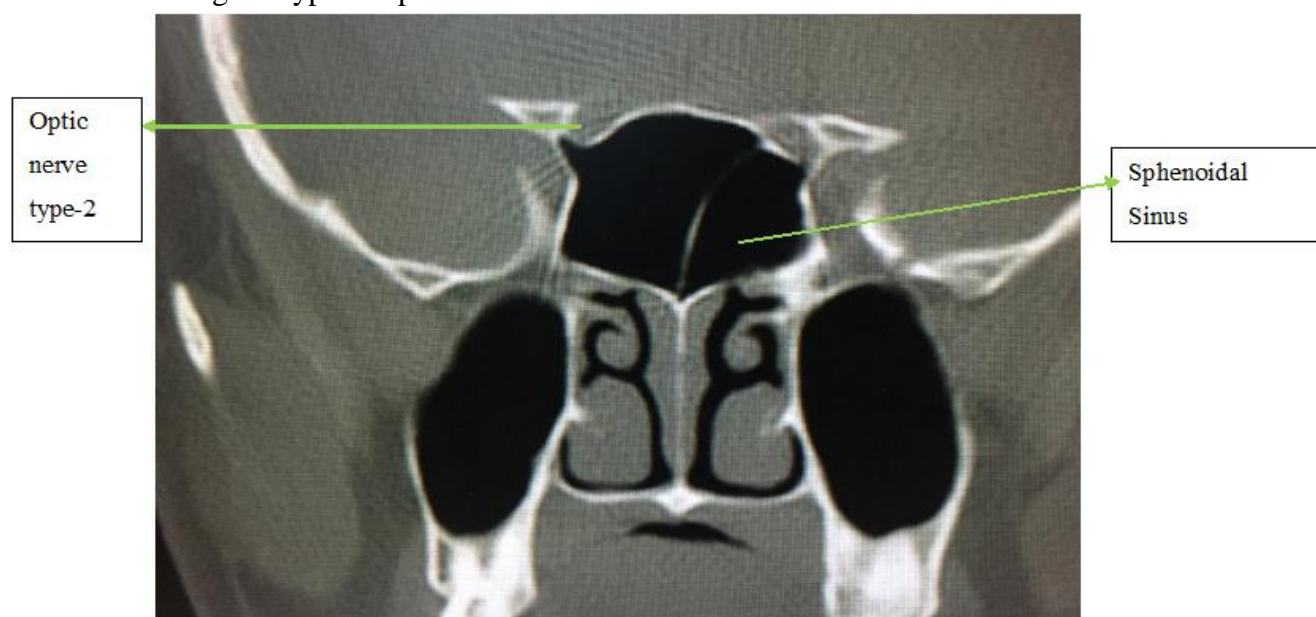
		Only type-1 both side		Total	p-value
		absence	presence		
range	1.00	10	11	21	.8
	2.00	23	16	39	
	3.00	11	8	19	
	4.00	8	6	14	
	5.00	3	4	7	
Total		55	45	100	

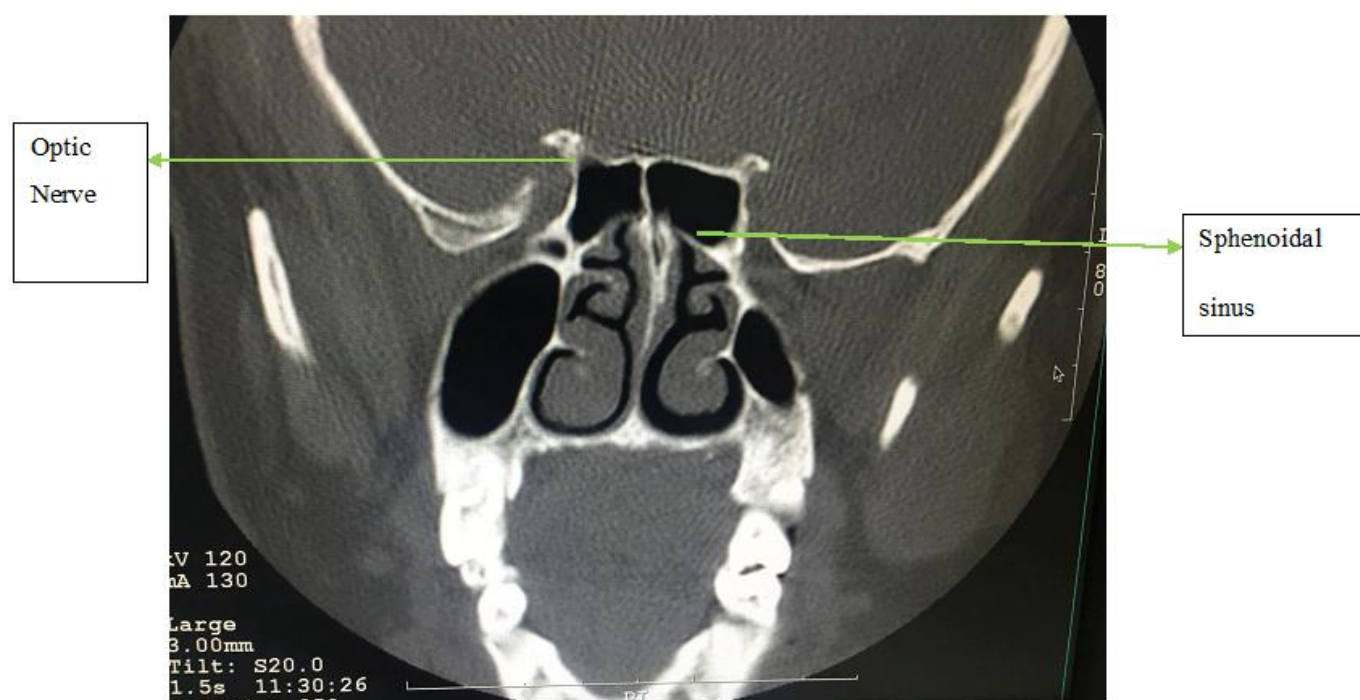
The above table showing the only Type-1 in both side. It is statically insignificant.

Table 8 According to the range Showing only the type-2 in both side

	Type-2 in both side		Total	p-value
	type2	absence		
1.00	4	17	21	0.5
2.00	7	32	39	
3.00	2	17	19	
4.00	1	13	14	
5.00	0	7	7	
Total	14	86	100	

The above tables showing the type-2 in both side and it is statically significant.

Picture 1 Showing the Type 1 in both side of sphenoidal sinus**Picture 2** Showing the types-2 sphenoidal sinus in both side

Picture 3 Showing the type-3 sphenoidal sinus in right side

References

1. Stephen F, Stephen G, Glenn F. Relationship of the optic nerve to the paranasal sinuses as shown in computed tomography. *Otolaryngol head neck surg.*1987;96:331.
2. Hewaidi GH, Omami GM. Anatomic Variation of Sphenoid Sinus and Related Structures in Libyan Population: CT Scan Study. *Libyan J Med.* 2008; 3(3): 128–33.
3. Rishikesh MI, Chaitra PA, Kiran KH etal. Optic Nerve Canal Relation to Posterior Paranasal Sinuses in Indian Ethnic: Review and Objective Classification. *Journal of Clinical and Diagnostic Research.* 2017 Apr, Vol-11(4): TC01-TC03
4. Mark C. DeLano, F. Y. Fun, and S. James Zinreich. Relationship of the Optic Nerve to the Posterior Paranasal Sinuses: A CT Anatomic Study. *AJNR*: 17, April 1996.669-665
5. Kinnman J. Surgical aspects of the anatomy of the sphenoidal sinuses and the sellaturcica. *J Anat.*1977;124:541-53.
6. Kaluskar SK, Patil NP, Sharkey AN. The role of CT scan in functional endoscopic sinus surgery. *Rhinology.*1993;31(2):49-52.
7. Cheung DF, Attia EL, Kirkpatrick DA, Marcarian B, Wright B. An anatomic and CT scan study of the lateral wall of the sphenoid sinus as related to the transnasaltransethmoid endoscopic approach. *J Otolaryngol* 1993; 22: 63-68.
8. Budu V, Carmen AM, Fanuta B. The anatomical relations of the sphenoid sinus and their implications in sphenoid endoscopic surgery. *Rom J Morphol Embryol.*2013;54(1):13–6.
9. DeLano MC, Fun FY, Zinreich SJ. Relationship of the optic nerve to the posterior paranasal sinuses: a CT anatomic study. *AJNR Am J Neuroradiol.* 1996; 17(4): 669-75.