



## Gastrocolic Fistula Following Endoscopic Cystogastrostomy - A Case Report

Authors

**Girish D. Bakhshi, Dayanand D. Choure, Kavita V. Jadhav, Uttam Wakadkar, Shekhar A. Jadhav, Mukund B. Tayade**

Dept of General Surgery, Grant Govt Medical College & Sir J J Group of Hospitals, Mumbai-400008, Maharashtra, India

Corresponding Author

**Dr Girish D. Bakhshi**

Devneeti, Plot-61, Sector-7, Koper Khairane, Navi Mumbai-400709, Maharashtra, India

Email: [gdbakhshi@yahoo.com](mailto:gdbakhshi@yahoo.com), Cell: +91-9820218198

### Abstract

*Gastrocolic fistula is an abnormal communication or a fistulous passage connecting the stomach and the colon. Normally it can be an outcome of peptic ulcer disease, malignancy of gastrointestinal tract, granulomatous colitis or trauma<sup>1-4</sup>. Gastrocolic fistula following endoscopic cystogastrostomy is a rare occurrence. We present a case of 22 years old male who developed gastrocolic fistula following endoscopic cystogastrostomy. A brief case report and review of literature is presented.*

**Keywords:** Pseudocyst, Endoscopy, Gastro-colic fistula.

### Introduction

Gastrocolic fistula can be benign or malignant, classified on the basis of its cause. The most common cause of gastric fistula is carcinoma of stomach<sup>1-5</sup> followed by gastric ulcer, granulomatous colitis, trauma, etc. Gastrocolic fistula resulting from the advanced neoplasia received frequent attention during the early part of century. Literature mentions mostly malignancies as the major cause of fistulas arising in the colon or stomach. With time, gastrocolic fistula became an unusual complication of benign gastric ulcer<sup>1</sup>. Later, reports in recent years have indicated that benign gastrocolic fistulae have increased in frequency. This may be due to the use of steroids

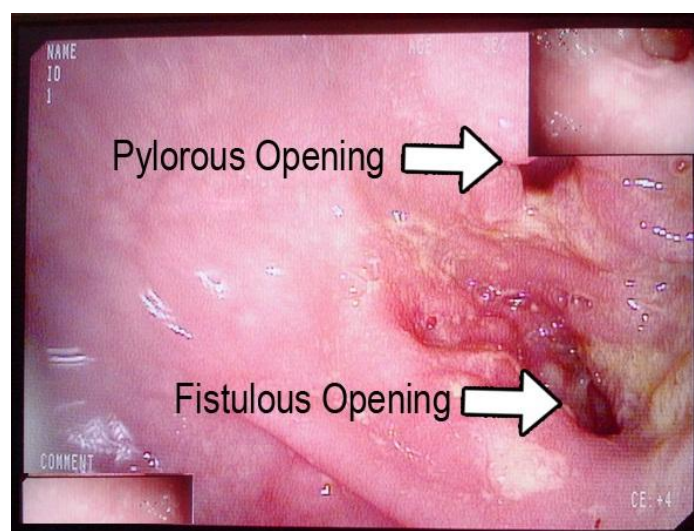
and acetylsalicylic acid preparations which may be playing a role in the etiology. The purpose of this paper is to report a rare case of gastrocolic fistula resulting from an endoscopic cystogastrostomy done for pancreatic pseudocyst. Case Report: A 22 years old male presented with complaints of pain in abdomen, eructation, nausea and faecal vomiting since 4 months. Patient gave past history of blunt trauma to abdomen 6 years back, being hit by the handle of a motorcycle in the epigastric region. Patient was admitted in a local hospital for 15 days and managed conservatively initially. However, patient developed severe epigastric pain and vomiting. He was referred to another hospital where Contrast

enhanced Computerized tomography (CECT) of Abdomen and Pelvis was done which was suggestive of Pancreatic transection at the junction of head and body with multiple peripancreatic collection and moderate ascites. Exploratory laprotomy with pancreatic necrosectomy with peritoneal toilet was done. Later, Endoscopic Retrograde Cholangiopancreatography (ERCP) was done and Pancreatic duct was cannulated for recurrent abdominal pain. Serial ultrasonographies done were suggestive of localized collection within the pancreatic parenchyma at the site of transection with mildly dilated pancreatic duct. CECT abdomen was suggestive of multiple, multiseptate, peripherally enhancing pseudopancreatic cysts in the peripancreatic and perihepatic regions. Later, Ultrasonography (USG) guided peripancreatic fluid aspiration was done and 300ml of clear fluid was removed. However, patient developed pseudocyst of pancreas again after the procedure. Patient underwent endoscopic cystogastrostomy 5 years back with placement of stent. Patient gave history of passage of stent in faeces 4 months back which he had preserved (Fig.1). Patient had present complaints of faeculent vomiting since 4 months. For these complaints patient was referred to our center. On upper GI-Scopy, faeces were seen in the stomach with reflux from the prepyloric region from an opening other than pylorus suggestive of gastrocolic fistula (Fig.2). Barium study confirmed a gastrocolic fistula (Fig. 3). CECT abdomen was suggestive of a gastrocolic fistula between the prepyloric region and transverse colon of length 5cm and opening in the prepyloric region with a defect of 2cm in size. Biopsy was taken to rule out malignancy. Exploratory laparotomy confirmed Gastro-colic fistula (Fig. 4). Intra-operative biopsy was taken. This fistula was dissected all around and was disconnected using Gastrointestinal staplers. Post-operative recovery was uneventful. Biopsy was suggestive of inflammatory tissue. Post-operative endoscopy done after 6 weeks showed healed

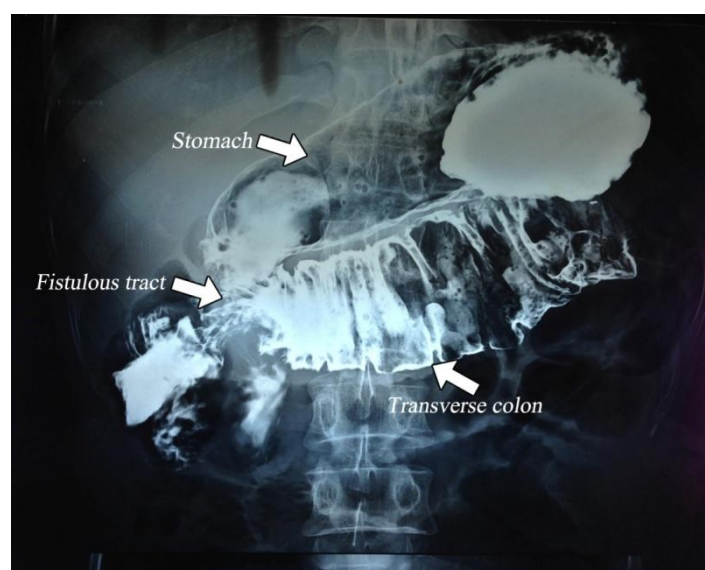
opening of fistula (Fig. 5). Follow up of 6 months has shown him to be disease and symptom free.



**Fig. 1)** Stent passed by patient in stool

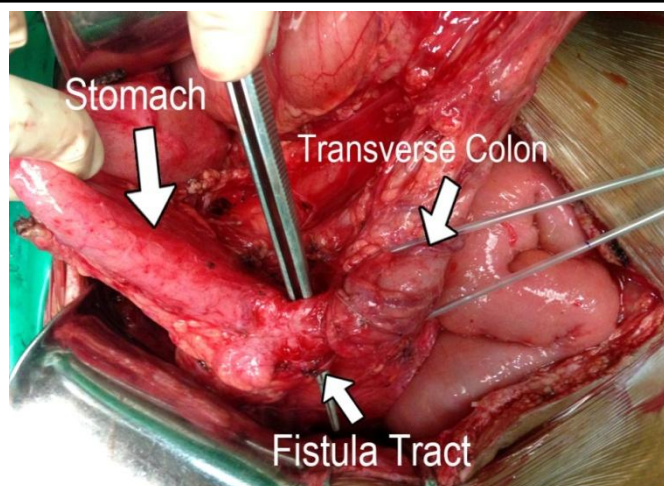


**Fig. 2)** Endoscopy showing gastric opening of gastrocolic fistula

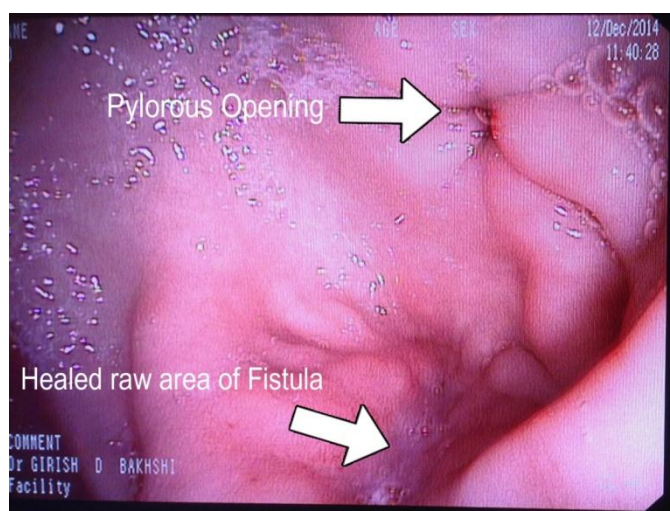


**Fig. 3)** Barium study showing gastrocolic fistula





**Fig. 4)** Intra-operative picture showing gastrocolic fistula dissected all around



**Fig. 5)** Post-operative endoscopy showing healed opening of gastrocolic fistula.

## Discussion

Gastrocolic fistula was first described by Haller in 1755. It has been described as benign or malignant. Malignancy of stomach or colon is considered to be the most common cause of gastrocolic fistula. However, in English literature, benign unoperated cases of gastric ulcer has been the etiology of gastrocolic fistula in 71 cases.<sup>2</sup> Other common etiologies of gastrocolic fistula include diverticulitis of the colon, inflammatory bowel disease, gastrointestinal tuberculosis, syphilis, trauma, irradiation, pancreatic abscess, perigastric abscess, granulomatous colitis and iatrogenic factors. Gastro-colic fistula has also been seen following PEG (Per-oral Endoscopic Gastrostomy) in few cases<sup>6</sup>. Present case is the

first case which is as a result of Endoscopic Cystogastrostomy. Symptoms of gastrocolic fistula in the order of its frequency include abdominal pain (83%), diarrhea (74%), weight loss (74%), vomiting (74%), faecal eructations or faeculent vomiting (55%), and significant gastrointestinal bleeding (38%).<sup>2</sup> Present case presented with pain in upper abdomen with faecal vomiting and weight loss. Gastrocolic fistula also leads to malabsorption syndrome. However, the cause of the same is presence of colonic contents by reflux into the upper intestinal tract leading to colonization of upper intestinal tract by the colonic flora rather than shunting of the gastric contents into the colon. The passage of gastric contents into the colon is however, less significant, and it mostly causes post meal diarrhoea.<sup>3</sup> Due to the colonization of the upper gastrointestinal tract, the digestive and absorptive capacity of the small bowel is hampered. So, this malabsorption and rapid transit leads to weight loss and severe nutritional deficiency. In present case the stent eroded from lesser sac into colon resulting in gastrocolic fistula. Investigations to confirm gastrocolic fistula include upper GI endoscopy, barium studies and CECT abdomen. In present study all three investigations confirmed the diagnosis. Surgery is the treatment of choice. Either fistulectomy with primary repair may suffice or sometimes, it may require one stage en bloc resection of the involved stomach and colon including the fistula tract with creation of Billroth I or II anastomosis.<sup>5,7</sup> In present case fistula was dissected all around and disconnected using GI staplers. Of the various causes responsible for the formation of a gastrocolic fistula, endoscopic cystogastrostomy stent eroding the colon, and leading to a gastrocolic fistula has not been described in literature till date. Present case demonstrates that endoscopic stent migration can take place from lesser sac into the colon resulting in gastrocolic fistula. Hence, while performing an endoscopic stenting procedure or dealing with a case of gastrocolic fistula, possibility of erosion by the stent should be considered as a cause of

gastrocolic fistula and hence follow up endoscopy should be done. This also compels us to think whether endoscopic stent placed for cystogastrostomy can be kept for long time. As keeping this stent may result into gastrocolic fistula. However, further studies are required to develop a defined guideline.

### Acknowledgement

We thank our Dean Padmashree Dr. T P Lahane for permitting us to publish this article.

**Conflict of Interest:** None

**Financial Support:** None

### References

1. Allison JE: Gastrocolic fistula as a complication of gastric lymphoma. Am J Gastroenterol 1973; 59:499–504.
2. Amlicke JA, Ponka JL: Gastrocolic and gastrojejunal fistulas: a report of sixteen cases. Am J Surg 1964;107:744-50.
3. Smith DL, Dockerty MB, Black M: Gastrocolic fistulas of malignant origin. Surg Gynecol Obstet 1972; 134:829–32.
4. Thoeny RH, Hodgson JR, Scudamore HH: The roentgenologic diagnosis of gastrocolic and gastrojejunal fistulas. Am J Roentgenol Radium Ther Nucl Med 1960; 83:876–81.
5. Verbrugge J. Gastrojejunal fistulae. Arch Surg 1925; 11:790-808.
6. Steven Y. Huang, Marc S. Levine, and Steven E. Raper; Gastrocolic Fistula with Migration of Feeding Tube into Transverse Colon as a Complication of Percutaneous Endoscopic Gastrostomy; American Journal of Roentgenology 2005; 184:S65-6.
7. Mathewson C. Preliminary colostomy in the management of gastrocolic and gastrojejunal fistulae. Ann Surg 1941; 114:1004-10.