



A Cadaveric Study on Division of Brachial Artery with Its Embryological Basis and Clinical Significance

Authors

Dr Gopal Bagal¹, Dr Savita Takale²

¹Associate Professor, ACPM Medical College, Dhule, Maharashtra, India-434002

²Associate Professor, CSMSS, Ayurvedic Medical College, Aurangabad, Maharashtra, India-434000

Corresponding Author

Dr Gopal Bagal

Associate Professor, Dept of Anatomy, ACPM Medical College, Sakri Road, Dhule, Maharashtra, India-434001

Email: drgopalbagal@gmail.com, Mob. No.888764156

ABSTRACT

The brachial artery begins as a continuation of third part of axillary artery at the distal border of teres major muscle and terminates by dividing into the radial and the ulnar arteries at a point about finger's breadth below the bend of elbow at the level of neck of radius. The present study was done on 30 cadavers in department of anatomy to find out any variations in the branching pattern of the brachial artery. In our study variation was found in one cadaver only. An unusual short segment of the brachial artery was found in the upper part of the arm on right side. It was dividing into radial and ulnar arteries at the level of insertion of the coracobrachialis muscle. High division of the brachial artery has a profound applied importance especially in the field of vascular surgery and radiology. This variation should be bore in mind before any vascular surgery in the region of the forearm or while interpreting arteriograms of the upper limb. Thus the knowledge of branching pattern of brachial artery is useful for physicians, surgeons, radiologist and interventionist in various surgical procedures and also for diagnostic and therapeutic approaches.

KEY WORDS: Brachial artery, High up division, Radial artery, Ulnar artery.

INTRODUCTION

The brachial artery usually begins as a continuation of the axillary artery at the distal border of tendon of teres major muscle and ends about a centimeter distal to the elbow joint at the level of neck of radius, by dividing into two branches, lateral one is called radial artery and medial one is ulnar artery. The brachial artery runs along a line from the medial lip of bicipital groove behind the coracobrachialis muscle to the middle of the cubital fossa at a point level with the neck

of the radius. The median nerve is closely related to the brachial artery. It lies lateral to the brachial artery in the upper part of the arm. The brachial artery gives profunda brachii artery, superior ulnar collateral artery, inferior ulnar collateral artery, muscular branches and the two terminal branches. According to compendium of Human Anatomic Variation, major variations are present in about 25% of the subject studied for the brachial artery. Frequently the artery divides more proximally than usual and this unusually short segment of

brachial artery may bifurcate as usual or it may trifurcate into radial, ulnar and common interosseous arteries. Most often radial artery arises proximally, leaving a common trunk for ulnar and common interosseous arteries. Proximal division of brachial artery is due to the failure to disappear proximal origin of radial artery and the radial artery does not establish new connection with main trunk near the origin of ulnar artery⁽¹⁾. Several other variations related to the termination of such a short segment brachial artery have been mentioned by some earlier workers. Such variations can be explained on the basis of embryonic development. According to Fienberg, ectodermal mesenchymal interactions and extracellular matrix components within the developing limb bud are controlling the initial patterning of blood vessels. Further, there is a view that some inductive factors from the limb mesenchyme cause the changes in the blood vessel pattern.

Brachial artery is used in routine procedure like, blood pressure recordings and arteriography of different parts of body. Variation in the branching pattern of brachial artery is noteworthy for vascular surgeons particularly in cases involving traumatic injuries. Radiologists also must be aware of these kinds of variations during various imaging studies. Distal part of brachial artery is chosen for pulsed dopler sonographic measurements⁽²⁾.

Appreciation of variations in the upper extremity vasculature is essential to prevent injury, thrombosis, gangrene and even amputation of limbs, particularly in patient requiring dialysis or undergoing arteriography. For both surgical and routine patient an accurate knowledge of course and relations to surrounding structures is of great importance⁽³⁾.

The aim of our study is to discuss the anatomy, embryological reasons for these kinds of variations and clinical significance along with relevant review of literature.

MATERIAL AND METHODS

The present study was done on 30 cadavers in the department of Anatomy. The specimens were dissected by using scalpel and forceps. An incision was made in the upper limb from axilla to the wrist. The muscles were dissected by removing adipose tissue and fasciae around and over them in order to show their origin, insertion, vasculature and innervations. Blood vessels and nerves were dissected by withdrawing the adjacent tissues. The brachial artery and its branches were exposed after classical dissection and separation of the muscles of the arm and forearm related to this artery.

RESULTS

Among the 30 cadavers variation was found in one cadaver only. In this cadaver, the brachial artery bifurcated into a medial and lateral branch 9 cm distal to the lower border of teres major muscle in the upper part of the arm. After origin both branches runs inferiorly. The medial branch crosses superficial to the lateral branch and median nerve from medial to lateral side in the lower part of arm and continued as radial artery in the forearm.

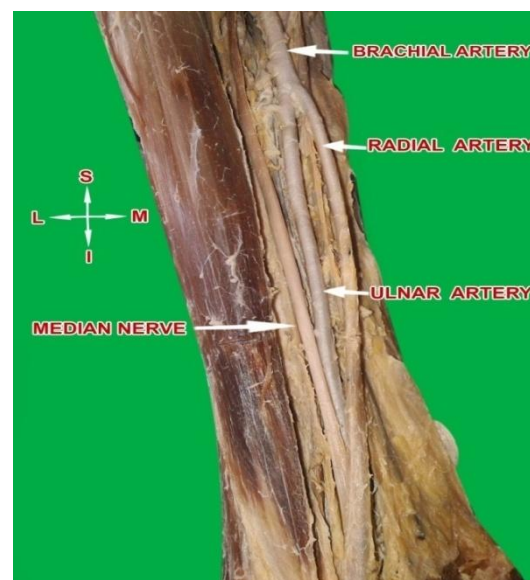


Photo.1: Photograph showing high division of brachial artery with origin of radial and ulnar arteries

The lateral branch runs deep to medial branch and medial to median nerve in the arm. The lateral branch was medial to median nerve in the upper and lower part of the arm. The lateral branch runs deep to the pronator teres muscle in the cubital fossa and trifurcated at the proximal proximal border of pronator teres muscle. One branch continued as similar course as that of ulnar artery forming the superficial palmar arch. The other two branches were muscular and common interosseous arteries.

DISCUSSION

The variations of the arterial system of the upper limb have been well documented by many authors and have a considerable significance towards the clinical and surgical point of view.

Arterial variation in the upper limb was noted for the first time by Von Haller in 1813⁽⁴⁾. It is not uncommon to find variation in the branching pattern of arteries of the upper limb⁽⁵⁾. The major variations in the arterial patterns reported are the higher origin of radial and ulnar arteries. This is mainly because of their multiple and plexiform sources, the temporal succession of emergence of principle arteries, anatomises and periarticular networks and functional dominance followed by regression of some path.

Arey and Jurjus mentioned six explanations for the variations in the blood vessels of upper limb⁽⁶⁾.

1. The choice of unusual paths in the primitive vascular plexus.
2. The persistence of vessels which are normally obliterated.
3. The disappearance of vessels of vessels which are normally retained.
4. An incomplete development.
5. The fusion and absorption of parts which are normally distinct.
6. A combination of factors leading to atypical pattern normally encountered.

In 1961, Keen mentioned high origin of radial artery from the brachial artery. He explained this variant on the basis of Arey's observation regarding anomalous blood vessels⁽⁷⁾. In fact,

Keen highlighted that there was persistence of the upper portion of the radial artery arising from the brachial artery proximal to the origin of ulnar artery followed by failure of development of new connection of the radial artery with the brachial artery at the level of origin of ulnar artery.

Guha et al. also observed high up division of brachial artery into radial and ulnar arteries in the middle of the arm associated with the variant median nerve and musculocutaneous nerve⁽⁸⁾.

High bifurcation of the brachial artery was found in only 0.5 % in 202 cadavers dissected by Bertolazzo, Romezo, Bica et al. in 1981⁽⁹⁾. In a Brazilian study involving 72 upper limbs of adult cadavers of both sexes, the bifurcation of the brachial artery was found above bicondylar line in 11.1% cases⁽⁹⁾. Nomani satyanarayana et al.2010, also documented a case of early division of brachial artery in middle of right arm into radial and ulnar artery both of same caliber⁽¹⁰⁾. High division of brachial artery in the proximal third of arm was found in 3 cases out of 60 specimens by Vandana R., N.M Suresh et al.2012⁽¹¹⁾. An unusually short segment of brachial artery with bifurcation proximal at the level of insertion of coracobrachialis was noted in 2 out of 20 cadavers by Jitendra Gupta et al 2012⁽¹²⁾. Higher division of brachial artery with superficial course of radial artery was found in 3 cases out of 48 cadavers in study by Dr. Padma Varlekar et al.2013⁽¹³⁾.

Following table shows the incidence of high origin of radial artery i.e. brachioradial artery, as reported by various workers.

Table 1. Incidence of origin of brachioradial artery, as reported by various workers ⁽¹⁴⁾

Sr.No.	Author & Year	Sample size	Brachioradial artery incidence	% incidence
1	Qualin, 1844	429	53	12
2	Muller, 1903	300	41	13.7
3	Adachi, 1928	410	29	7
4	McCrack, 1953	750	107	14.3
5	Weathersby, 1956	408	64	15.6
6	Skopakoff, 1959	610	55	9
7	Keen, 1961	284	17	5.9
8	Wankoff, 1962	800	78	9.7
9	Rodriguez-Baeza, 1995	150	6	4
10	Rodriguez-Niedenfuhr, 2000	385	53	13.8

Sometimes radial artery may arise from axillary artery. Following table shows the incidence of origin of radial artery from axillary artery by various workers.

Table 2. Origin of radial artery from axillary artery in different studies

Authors	Year	Percentage (%)
Keller et al.	1980	2.13
Uglietta et al.	1989	2
Baeza A et al.	1995	0.66
Niedenfuhr et al.	2001	10.40
Konarik et al.	2009	3
Vandana et al.	2012	8.30
Chandni Gupta et al.	2012	2.66
Subhash m. et al.	2013	3.33

In our study early bifurcation of brachial artery was found in the upper one third of right arm in one cadaver only out of 30 cadavers.

EMBRYOLOGY

The anomalies of various blood vessels of upper extremity can be explained on the basis of embryological development of the vascular plexus of limb buds. The early limb bud receives blood via intersegmental arteries, which contribute to a primitive capillary plexus. At the tip of the limb bud there is a terminal plexus that is constantly renewed in a distal direction as the limb grows. Later, one main vessel supplies the limb and the terminal plexus; it is termed the axis artery ⁽¹⁵⁾.

In the upper limb bud, the axis artery is derived from the lateral branch of the seventh intersegmental artery i.e. subclavian artery. The proximal part of the main trunk of this artery forms axillary and brachial arteries and its distal part persist as anterior interosseous artery and deep palmar arch. Radial and ulnar arteries are last

to appear in the forearm from the axis artery, that is brachial artery. Initially, the radial artery arises from more proximally than the ulnar artery. Later, it establishes a new connection with the main trunk at/or near the level of ulnar artery. The upper portion of its original stem usually disappear to a large extent.

The persistence of the upper portion of the radial artery arising from the brachial artery proximal to the origin of ulnar artery followed by failure of development of the new connection of the radial artery with the brachial artery at the level of origin of ulnar artery causes this type of anomaly ⁽¹⁶⁾.

CONCLUSION

Thus any of the factors affecting during development of limb vessels will lead to anomalies in the level of division of major

arteries. These variations are having practical importance for the radiologists, cardiologists, and orthopedics and vascular surgeons. Last but not least, the knowledge of this variation is important for the clinicians in day to day practice for measurement of blood pressure using sphygmomanometer cuff in the arm. Any patient visiting to casualty full imaging of this branching pattern is neither feasible, nor cost effective. Hence it is important to keep in mind possibility of this kind variation before initiating any procedure.

REFERENCES

1. Shewale SN, Sukre SB, Diwan CV. Bifurcation of brachial artery at its commencement: A case report. Biomedical research.2012; 23(3):453-456.
2. Ozcan H, Oztekin PS, Zergeroglu AM, Ersoz G. Doppler ultrasound evaluation of the structural and hemodynamic changes in the brachial artery following two different exercise protocol. Diagn.Interven.Radiol.2006; 12(2):80-84.
3. Chandni Gupta, Vikram Palimar, Murlimanju BV, Vaishali R. A morphological study of variations in the origin and course of radial artery. Research Journal of Pharmaceutical, Biological and Chemical sciences.2012; 3(2):333.
4. Bidarkotimath S, Avadhani R, Kumar A. An anatomical study of primary pattern of arteries of upper limb with relevance to their variations. Int. J. Morphol.2011; 29(4):1422-1428.
5. Agrawal D, Singh N, Mohanti BB, Chinara PK. Variation in the branching pattern of axillary artery-a case report. Int J Anat Var.2013; 6:31-33.
6. Kachlik D, Konarik M, Baca V. Vascular patterns of upper limb: an anatomical study with accent on superficial brachial artery. Bosnian Journal of Basic medical Sciences.2011; 11(1):4-10.
7. Keen JA. A study of the arterial variations in the limb, with special reference to symmetry of vascular patterns. Am J Anat.1981; 108:245-261.
8. Guha R, Palit S. A rare variation of anomalous median nerve with absent musculocutaneous nerve and high up division of brachial artery. J Interacad.2005; 9:398-403.
9. Subhas M, Gujar et al. A study on division of brachial artery and its clinical correlation. Int J Anat Res.2014; 2(1):208-212.
10. Namanni Satyanarayana et al. Brachial artery with high up division with its embryological basis and clinical significance. Int. J Anatomical variations.2010; 3:58.
11. Vandana R et al. Variation in course and branching pattern of brachial artery. Anatomica Karnataka 2012; 6(3):42-48.
12. Jitendra Gupta et al. A study of brachial artery with high up division and its clinical significance. Int J Bioassay.2012; 01(11):116-118.
13. Padma Varlekar et al. Higher bifurcation of brachial artery with superficial course of radial artery in forearm. Int. J of Med Sci. Public Health.2013; 2:703-706.
14. Pokhrel r, Bhatnagar R. Unilateral high bifurcation of brachial artery. OA Anatomy.2013; 1(4):34.
15. Patnaik, VVG, Kalsey G, Singlarajan K. Branching pattern of brachial artery-A morphological study. J Anat. Soc India.2002; 51(2):176-186.
16. Satyanarayan N, Sunita P, Sheikh MM, Devi SP. Brachial artery with high up division with its embryological basis and clinical significance. Int. J Anat. Var. 2010; 3:56-58.