



Jansen Type Metaphyseal Chondrodysplasia-A Rare Presentation (CASE REPORT)

Authors

Dr Abir Lal Nath¹, Dr Shweta Nair², Dr Rajdeep Pal³

¹MBBS, PG Student MD Pediatrics Department of Pediatrics DY Patil Medical College

²MBBS, PG Student MD Pediatrics Department of Pediatrics DY Patil Medical College

³MBBS, PG Student MD Pediatrics DY Patil Medical College

DY Patil Medical College Navi Mumbai India

Abstract

Metaphyseal chondrodysplasia previously known as metaphyseal dysostosis, is a rare autosomal dominant disorder of endochondral ossification, characterized by accumulation of cartilage in various skeletal sites, specifically metaphysis of tubular bones(1). Clinical diagnosis is made on the basis of short stature with bowing of the legs in newborn period or early infancy. There is marked widening of the joints with contractures. Striking radiological changes include expanded and cup shaped metaphysis with normal epiphysis and diaphysis(2). Half the number of the cases may have hypercalcemia and hypophosphatemia(3,4). This entity may simulate rickets refractory to vitamin D, renal tubular acidosis, renal osteodystrophy, hyperpara-thyroidism or hypophosphatasia(5). We report a 1 year old female with complain of history of birth at 32 weeks gestation presented with early onset of multiple bony deformities. Her birth weight was 2.5 kilograms. Nasogastric feeding was given for the initial few weeks of her life. Widening of wrists, knees and ankle joints, and chest deformities were noticed at the age of one month. Despite the administration of calcium and vitamin D her deformities worsened. There was no history of parental consanguinity or family history of metabolic bone disease.

Keywords: *Metaphyseal chondrodysplasia, metaphyseal dysostosis*

INTRODUCTION

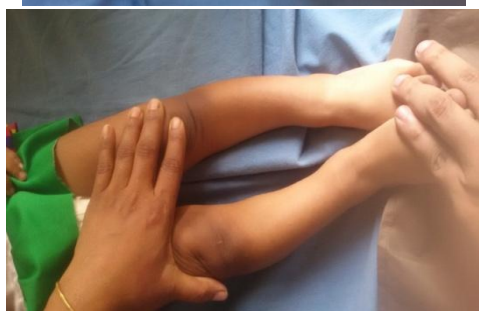
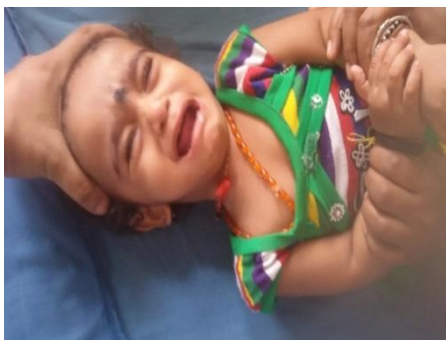
Jansen type metaphyseal chondrodysplasia is an extremely rare progressive disorder in which portions of the bones of the arms and legs develop abnormally with unusual cartilage formations and subsequent abnormal bone formation at the large (bulbous) end portions (metaphyses) of these long bones (metaphyseal chondrodysplasia). As a result, affected individuals exhibit unusually short arms and legs and short stature (short-limbed

dwarfism), findings that typically become apparent during early childhood. Abnormal cartilage and bone development also affect other bones of the body, particularly those of the hands and feet (i.e., metacarpals and metatarsals).

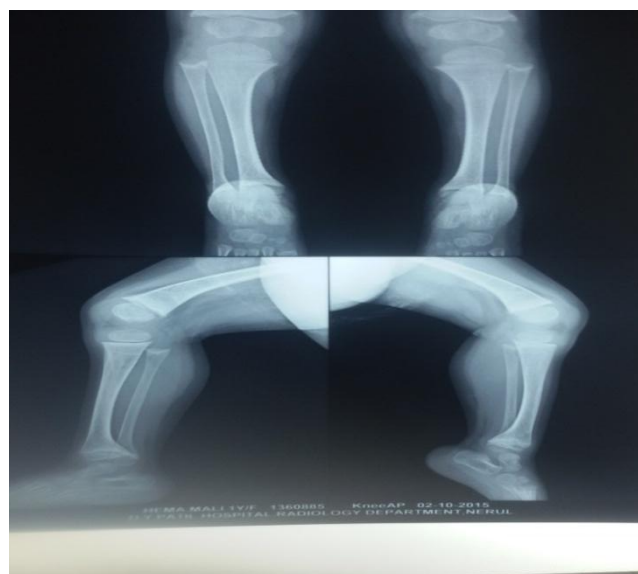CASE REPORT

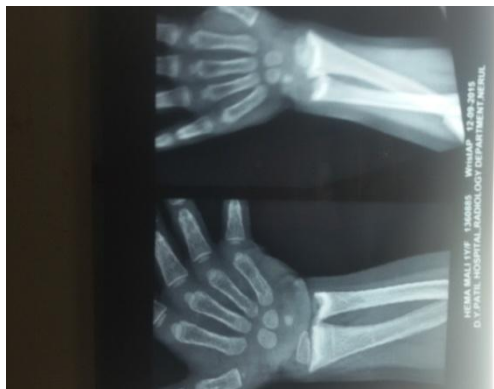The patient was female 1 year with history of birth at 32 weeks gestation presented with early onset of multiple bony deformities. Her birth weight

was 1.5 kilograms. Nasogastric feeding was given for the initial few weeks of her life. Widening of wrists, knees and ankle joints, and chest deformities were noticed at the age of one month. She had normal hair, skin and eyes. She had bowing of upper and lower limb long bones, widening of wrists and ankle joints. Contractures of left elbow, right hip and both knee joints (flexion deformities) were present. Flexion deformities were also present at proximal interphalangeal joints. Frontal bossing, rachitic rosary, Harrison's sulcus were present. The spine was normal on clinical examination. The patient had generalized hypotonia with normal reflexes, without any sensory nerve involvement. Rest of the systemic examination was normal. Laboratory investigations revealed serum calcium 10.3 mg/dl, phosphorus 4.8 mg/dl and alkaline phosphatase 583.2iu/l. Twenty-four hour urinary excretion of calcium was 52 mg and phosphorus 175 mg. Hematological parameters, blood urea, serum creatinine and serum electrolytes were normal. Her renal tubular absorption of phosphate was 84%.25 hydroxy vit d-above 160. The child exhibit unusually short arms and legs and short stature. diminished muscle mass and gradual swelling of certain joints, particularly the hips and knees. Affected joints may become stiff and painful and certain movements, particularly bending (flexion), may become limited.



Radiological investigations: Radiographs of the upper extremity (Fig. 2) showed marked widening and fraying of the metaphyses of humerus, radius and ulna with an irregular fragmented appearance.





Severe metaphyseal irregularity, widening and fragmented appearance with diaphyseal bowing were also seen to involve the femur, tibia and fibula (*Fig. 3*). The epiphyses of the long tubular bones of both the upper and lower extremities were bulbous.

Child had diminished muscle mass and gradual swelling of certain joints, particularly the hips and knees. Affected joints may become stiff and painful and certain movements, particularly bending (flexion), may become limited.

DISCUSSION

Infants with Jansen type metaphyseal chondrodysplasia may also have characteristic facial abnormalities and additional skeletal malformations. During childhood, affected individuals may begin to exhibit progressive stiffening and swelling of many joints and/or an unusual "waddling gait" and squatting stance. In addition, affected adults may eventually develop abnormally hardened (sclerotic) bones especially in the back of the head (cranial bones), which, in some cases, may lead to blindness and/or deafness. In addition, affected individuals have abnormally high levels of calcium in the blood (hypercalcemia). The range and severity of symptoms may vary from case to case. Most cases of Jansen type metaphyseal chondrodysplasia occur randomly as the result of a spontaneous genetic change (i.e., new genetic mutation).

REFERENCES

1. Charrow J, Poznanski AK. The Jansen type of metaphyseal chondrodysplasia: Confirmation of dominant inheritance and review of radiographic manifestations in the newborn and adult. *Am J Med Genet* 1984; 18: 321-327.
2. Nazara Z, Hernandez A, Corona-Rivera E, Vaca G, Panduro A, Martinez-Basalo C, *et al.* Further clinical and radiological features in metaphyseal chondrodysplasia Jansen type. *Radiology* 1981; 140: 697-700.
3. Gordon SL, Varano LA, Alandete A, Maisels MJ. Jansen's metaphyseal dysostosis. *Pediatrics* 1976; 58: 556-560.
4. Parfitt AM, Schipani E, Rao DS, Kupin W, Han ZH, Juppner H. Hypercalcemia due to constitutive activity of parathyroid hormone (PTH)/PTH-related peptide receptor: Comparison with primary hyperparathyroidism. *J Clin Endocrinol Metab* 1996; 81: 3584-3588.
5. Silver thorn KG, Houston CS, Duncan BP. Murk Jansen's metaphyseal chondrodysplasia with long-term follow up. *Pediatr Radiol* 1987; 17: 119-123.