



Primitive Neuroectodermal Tumor (PNET) of Kidney - A Case Report

Authors

Dr Ajamal Singh Bhayal¹, Dr Surbhi Rajauria³, Dr Ramesh C. Purohit³

¹M. D. (Pathology) Associate Professor, Department of Pathology, RUHS College of Medical Sciences, sector 18 Pratap Nagar Jaipur (Raj) 302033.

²D.N.B. (Pathology). Assistant Professor, Department of Pathology, Dr. S.N. Medical College, Jodhpur, (Rajasthan).342001

³M.D. (Path. & Bact.), F.I.C.P., I.F.C.A.P; R.P. Diagnostic Centre, Opp. Sardar Children School, Hakim Bagh, Jodhpur, (Raj.).342001

Abstract

Primary primitive neuroectodermal tumor of kidney is a rare entity. They are aggressive tumors, have tendency of vascular invasion and metastasizing to lungs, liver and bones. Classically the tumor comprises of small round cells arranged in sheets with presence of pseudo-rosettes. The tumor needs an accurate diagnosis from other round cell tumors as the treatment and prognosis varies with each one. This report documents a case of PNET of kidney in a 35 year old female.

Keywords:- Primitive neuroectodermal tumor, Kidney, Ewings sarcoma, malignant.

Introduction

Primitive neuroectodermal tumor (PNET) is a malignant small round blue cell tumor belonging to Ewings (EW) family of tumors. EW tumors are primarily bone lesions and a small percentage arises in soft tissues, commonly chest wall, paravertebral region, pelvis, proximal extremities of adolescents and young adults. Among organ system kidneys are most common site. We report This case in a 35 year old female who presented with vague complaints and was diagnosed with right renal mass. This rare entity is briefly discussed with review of relevant literature.

Case Report

A 35 year old female presented with abdominal heaviness, discomfort and dull aching pain at times. There was no history of hematuria or

dysuria. The patient was advised routine blood investigations along with abdominal ultrasonography. USG revealed a large mass in Rt kidney. Intra venous pyelography was performed which showed distortion of calyces. Blood investigations revealed mild anemia with raised ESR. Other tests were within normal range. Radical nephrectomy was performed and sent for histopathological examination.

Pathologic findings

Macroscopic examination showed a nephrectomy specimen covered with perinephric fat measuring 11.5 x 6.5 x 8 cm. External surface was lobulated and well encapsulated. Stump of ureter was 3.8 cm. Cut surface showed a well circumscribed mass of 5.4 cm diameter situated at lower pole of kidney and was seen protruding into the calyces

.The mass was grey-white to brown with areas of necrosis giving a variegated appearance. The upper pole showed a mass of 3 x 3 x 3 cm. Cortex and medulla were poorly defined. Ureter was filled with blood. Microscopic examination revealed a malignant tumor comprised of round to oval cells arranged in sheets. with presence of pseudorosettes. At places areas of necrosis were present and the tumor was mitotically active but not brisk. Vascular invasion was present. The cells were PAS positive. Immuno histochemistry was performed. The tumor was CD 99 positive but negative for CD-45, pancyto keratin and chromogranin A and finally diagnosed as primitive neuroectodermal tumor of kidney (PNET).

**Metropolis Healthcare Jodhpur
(R.P. Diagnostic Centre)**

IMMUNO-HISTOCHEMISTRY REPORT

Patient's name: Mrs XXX

Age : 30 years Sex : Female

Ref. by: Dr. XXX

Date Received 29-09-12

Ref.: RP/IHC/061-12

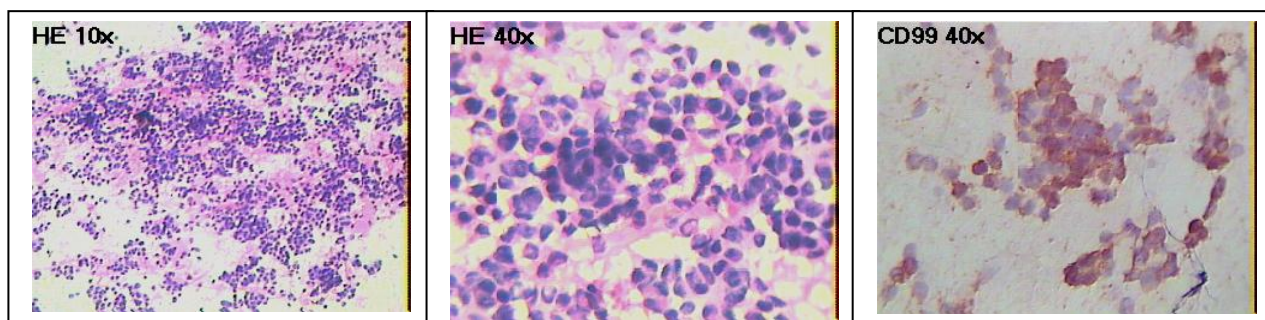
Date test done 30-09-12

S. N. : 006

Sample received: Unstained paraffin sections

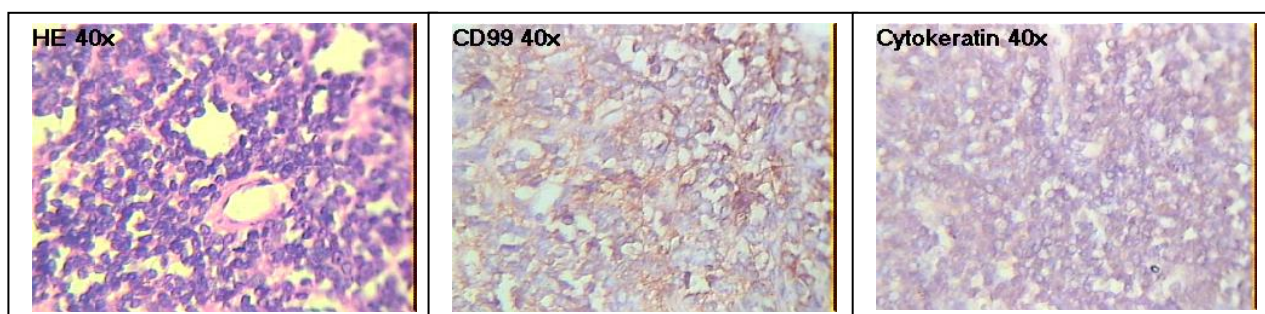
Microscopic Examination: Malignant round cell tumor ?PNET/Ewings.

CD99 : POSITIVE



Impression: EWINGS'/PNET.

CK : NEGATIVE



Impression: Primitive Neuroectodermal tumor / EW kidney.

Interpretation

CD99 (MIC2 antigen)

CD99 is a 32 kD membrane glycoprotein expressed by human thymocytes, most T-ALL cells, some red blood cells and the small round tumors of Ewings sarcoma and Primitive

neuroectodermal tumors. It is found to be expressed in lymphoblastic lymphomas, large cell lymphomas and paediatric acute lymphocytic leukemia and Askin-Rosai tumor.

Pancytokeratin (Cytokeratin cocktail)

Human cytokeratins (40kD to 68kD) are a family of water insoluble Proteins that form a major part of the cytoskeleton of epithelial cells. Immunohistochemical analysis of a large number of tumors has established keratin protein immunohistochemistry as an important aid for classification of epithelial neoplasms. Monoclonal antibodies AE1 and AE3 recognize the acid and basic subfamilies of cytokeratin respectively. Thus, the combination of these two antibodies can be used to detect almost all human epithelia. These antibodies do not show any cross reactivity with other cytoskeletal proteins. This cocktail has been used to differentiate epithelial tumours from non-epithelial tumours.

Discussion

Primitive neuroectodermal tumor was initially described as blue round cell tumor by Arthur Purdy Stout and his colleagues in 1918. Later it was described by Askin and his colleagues as a peculiar small cell tumor of chest wall in adolescents (Askin's tumor)⁽¹⁾. Ewings and PNET's are biologically related tumors There is gene fusion FLI-1 gene on chromosome 11 with EWS gene on chromosome 22 (11,22) (q 24,q12) (4). A variety of fusions may occur. DNA Transcriptor factor (EWS) is joined to RNA binding factor (FLI1) leading to abnormal DNA regulation. These tumors show CD 99 positivity in 95% of cases (3) also known as MIC-2 Antigen, 12 ET, E2, O13, HBA71(5)(7) which are derived from lymphoblastic cells lines.

Differential Diagnosis of PNET is with Extrasosseous EWS, Rhabdomyosarcoma (solid alveolar type). Neuroblastoma, Nephroblastoma (Wilm's tumor), carcinoid, clear cell sarcomas of kidney, desmoplastic round cell tumor and lymphoma etc.

Extraskeletal Ewings sarcomas lack Homer Wright rosettes which are the hall mark of primitive neuroectodermal tumors. The cells are arranged in diffuse sheets in compressed cellular masses, nuclear contours are same as lymphoid cells but slightly larger. Cytoplasm is clear or

bubbly with abundance of glycogen giving PAS positively. The cell interspersing creates a light and dark cell pattern. The mitotic activity is low in typical Ewings sarcoma. These tumors often regress after the therapy leaving a fibrous scar and microscopically residual viable tumors in fibrous tissue.

Common mimic of tumor in Ewings family is solid variant of alveolar rhabdomyosarcoma in which cells are separated by prominent framework of fibrovascular septas resembling lung alveoli, sometimes giving a picket fencing arrangement. Multiple tumor giant cells are usually seen. Immunohistochemistry resolves the confusion as these are cytokeratin and S100 protein negative but positive for myoglobin, MyoD1, skeletal muscle myogenin, skeletal muscle myosin and desmin.

Neuroblastomas show true rosettes with neuropils, salt and pepper chromatin. They are positive for synaptophysin, chromogranin A, synaptophysin neurofilament protein and microtubules associated protein.

Nephroblastoma (Wilm's tumor) show triphasic pattern blastemal stroma and epithelium, although biphasic and monophasic pattern can be seen. Stroma is myxomatous with presence of other mesenchymal elements. Rosette and glandular structures may be seen. Immunohistochemistry, though not of diagnostic help but nuclear reactivity for WT 1 in blastemal or epithelial element is characteristic.

Clear cell sarcoma of kidney histologically reveals monomorphic cords of cells separated by delicate vascular channels, tendency to surround isolated nephrons and prominent collagenous background. The tumors are negative for all markers except vimentin.

Desmoplastic round cell tumor is a small cell tumor encircled by dense. fibrotic tissue, vague rosettes with rhabdoid features. They are positive for desmin or vimentin, EMA, cytokeratin NSE, S100 protein, synaptophysin and CD 57.

The problem arises with lymphomas and poorly differentiated synovial sarcomas as both have tendency towards CD99 positivity. Lymphomas

have monomorphic appearance and are usually common leucocyte antigen (CD45) positive while synovial sarcomas are positive for cytokeratin subtypes.

To conclude a newer antibody to the FLT-1 proteins, product of EWS-FLT-1(2)(3)(6) fusion genes has been found to offer improved specificity with Ewing's sarcoma/primitive neuroectodermal tumors although it was not performed in this case.

References

1. Askin FB, Rosai J, Sibley RK et al: Malignant small cell tumor of thoracopulmonary region in childhood a distinctive clinical pathologic entity of uncertain histogenesis. *Cancer* 1979;43(6):2438-2451.
2. Jimenez RE, Folpe AL, Laphan RL et al: Primary Ewing's sarcoma/primitive neuroectodermal tumor of kidney. a clinic-pathologic and immunohistochemical analysis of 11 cases. *Am J Surg Pathol* 2002;26(3):320-327.
3. Folpe AL, Hill CE, Parham DM et al: Immunohistochemical detection of FLT-1 protein expression A study of 132 round cell tumors with emphasis on CD 99 positive mimics of Ewing's sarcoma/primitive neuroectodermal tumors. *Am J Surg Pathol* 2000;24(12):1657-1662.
4. Downing JR, Head DR, Parham DM et al: Detection of the (11;22)(q24;q12) translocation of Ewing's sarcoma and primitive neuroectodermal tumor by reverse transcription polymerase chain reaction. *Am J Pathol* 1993;143(5):1294-1300.
5. Papp AJ, Dauglas EC, Meyer WH et al: Use of HBA-71 and anti beta 2 microglobulin to distinguish primitive neuroepithelial from neuroblastoma. *Hum Pathol* 1993;24(8):880-885
6. Ohno T, Ouchida M, Leel et al: The EWS gene involved in Ewing family of tumors, malignant melanoma of soft parts and desmoplastic small round cell tumors,

codes for RNA binding protein with novel regulator domains. *Oncogene* 1994; 9(10):3087-3097.

7. Weidner N, Toje J: Immunohistochemical profile of monoclonal antibody O 13: antibody that recognizes glycoprotein p 30/32 MIC 2 and is useful in diagnosing Ewing's sarcoma. *Am J Surg Pathol* 1994;18(5):486-494.

About Authors




Dr Ajamal Singh Bhayal, MBBS, MD

Associate Professor, Department of Pathology, RUHS College of Medical Sciences. 109 B, Rajendra Nagar, Shyam Path, Sirsi Road, Jaipur (Raj) 302021 Email: asbhayal@gmail.com, Mob No.: 9680824505



Dr Surbhi Rajauria

C/O Lt Col. Prashant Rajauria, Medical Officer, M.H. Wellington, Nilgiri District. Tamilnadu. Email: srajauria@gmail.com, Mob.: 9785089589



Dr. Ramesh C Purohit, MBBS, M.D,

(Path. & Bact.), F.I.C.P., I.F.C.A.P.; R.P. Diagnostic Centre, Opp. Sardar Children School, Hakim Bagh, Jodhpur, (Raj.). 342001 Email: dr.rameshpurohit@gmail.com. Mob No.: 9799995975