



Oral and Dental Malformations Associated with Treacher Collins Syndrome

Ibrahim Gataa

School of Dentistry/ University of Sulaimani, Sulaimanya, 053 Iraq

Email: dribsg@yahoo.com Mobile Number: 009647701467775

Abstract

Treacher Collins syndrome (TCS) is a congenital craniofacial anomaly inherited as an autosomal dominant condition affects both sexes equally with wide variable deformities. The purpose of this study was to highlight the dental and oral malformations associated with this syndrome. A total of eight cases diagnosed to have the syndrome according to minimal obligatory criteria which are malar hypoplasia and downward slanting palpebral fissures were included in the study. Patients' data were recorded in special formula in addition to oral and dental deformities. Seven patients were males one female their age ranged from 10 to 23 years with normal mental status. All patients showed downward slanting palpebral fissures, malar hypoplasia. Four patients showed lower eyelid coloboma while six patients (75%) have partial absence of the eyelashes. Oral findings were high arched palate in all cases, malocclusion in 6 cases (75%) and macrostomia in 4 cases (50%) while multiple impactions of the teeth were detected in four patients. Cleft palate was detected in one case. Dental and oral anomalies associated with this syndrome should be considered in the treatment plan as soon as possible this will improve the quality of the life of the patients and decrease syndrome complications.

Keywords: Treacher Collins Syndrome; Mandibulofacial Dysostosis; Craniofacial Anomalies ; Coloboma,

Introduction

Treacher Collins syndrome (TCS) or Mandibulofacial dysostosis (MFD) is a congenital craniofacial anomaly inherited as an autosomal dominant condition affects both sexes equally. The incidence of TCS estimated as 1 /25000 to 1/50000 live births. The syndrome results from abnormalities in the first and second branchial arches morphogenesis occur between 3rd and 8th week of embryonic life^(1,2).

Early reports of this disorder were done by Thomson 1846, Berry 1889 and Treacher Collins 1900 whereas Franceschetti and Klein in 1944 used the term "mandibulofacial dysostosis," to describe the syndrome^(3,4).

Treacle or TCOF1 gene founded to responsible for the development of TCS. This gene is located in chromosome 5 q32-q33.1 and plays an important role in survival of neural crest cells. It is essential for craniofacial growth mainly the fusion of frontonasal processes and branchial arches of embryo. Mutation of TCOF1 gene which is a part of rRNA causes premature cell death of neural crest cell and development of the syndrome⁽⁵⁾.

Although fully expressed TCS can be easily diagnosed clinically minor manifestation of the syndrome make its identification is problematic based on the point that about 60% of the syndrome results from new mutations^(5,6).

This syndrome cause deformities in structures derived from the first and second branchial arches. The anomalies affect both hard and soft tissues bilaterally and symmetrically like zygoma, ears, eyes, maxilla and mandible.

According to Marsazlek et al.⁽⁶⁾ and Behrent et al.⁽⁷⁾ characteristics of TCS can be categorized into obligatory, common and infrequent features as in Table (1).

Patients with Treacher Collins syndrome showed several abnormalities in the oral cavity and the face. Deformities like malocclusion, changes in facial skeleton growth, micrognathia, retrognathia, open bite, macrostomia, temporomandibular joint hypoplasia, cleft palate and abnormalities of the teeth had been reported by many authors⁽⁶⁻⁹⁾. The purpose of this study was to highlight the dental and oral anomalies associated with this syndrome.

Table (1): Features of Treacher Collins Syndrome

<i>Obligatory features</i>	<i>Common features</i>	<i>Infrequent features</i>
Antimongoloid palpebral fissures	Malocclusion	Hypertelorism
Coloboma of lower eyelids	Open bite	Colobomas of upper lid
Eyelash malformation	Deafness	Cleft palate
Mandible defect	Macrostomia	Parotid gland agenesis
Malar hypoplasia	Nasal deformity	Frontal sinus deficiency
Preauricular hair displacement	High arched palate	Styloid process malformation
Micrognathia	Auricular malformation	Mental retardation
Fish like appearance	Skeletal deformity	Sella turcica defect

Material and Method

A total of eight cases diagnosed as TCS according to minimal obligatory criteria which are malar hypoplasia and downward slanting palpebral fissures were included in the study. These patients attended Maxillofacial Surgery Clinic in Sulaimani Teaching Hospital.

Patients' data were recorded in addition to clinical and radiographical examinations besides family history. Findings were documented in special formula arranged for this purpose. The study was approved by the ethical committee of the School of Dentistry / University of Sulaimani. Informed consent was taken from the patients or the parents in case of child patient to be participate in the study. Descriptive analysis was used to explain the results.

Result

Seven patients were males one female their age ranged from 10 to 23 years and have normal mental status. Two of the patients had positive family history for related features. Clinically all patients in this study (100%) showed downward slanting palpebral fissures, malar hypoplasia.

Four patients (50%) showed lower eyelid coloboma while six patients have partial absence of the eyelashes (75%) as presented in Table (2) and Figures (1). Oral findings were high arched palate in all cases, malocclusion in 6 cases and macrostomia in 4 cases while multiple impactions of the teeth were detected in four patients see Figure (2). Cleft palate was detected in one case as in Table (3). For radiographical manifestation of the syndrome zygomatic hypoplasia was founded in all cases followed by maxillary sinus hypoplasia in 7 cases Table (4) and Figure (3).

Table (2): Facial anomalies in studied patients

Facial features	NO.1	NO.2	NO.3	NO.4	NO.5	NO.6	NO.7	NO.8
Antimongoloid palpebral fissure	+	+	+	+	+	+	+	+
Coloboma	+	+	-	-	-	-	+	+
Absence of the lower lid lashes	+	+	-	-	+	+	+	+
Malar hypoplasia	+	+	+	+	+	+	+	+
Retruded mandible	-	+	+	+	-	+	-	+
Ear anomalies	-	+	+	-	+	-	-	+
Atypical hair growth	+	+	-	-	+	-	-	-
Obliteration of frontonasal angle	+	+	-	-	+	-	-	+
Prominent antgonial notch	+	+	+	+	+	-	+	-

(+) Presence, (-) Absence.

Table (3) Oral manifestations of the syndrome

Oral features	NO.1	NO.2	NO.3	NO.4	NO.5	NO.6	NO.7	NO.8
Macrostomia	+	+	-	-	+	-	-	+
High palate	+	+	+	+	+	+	+	+
Cleft palate	-	-	-	-	-	-	+	-
Malocclusion	-	+	+	-	+	+	+	+
Anterior open bite	-	+	-	-	+	-	+	+
Multiple impactions	-	+	-	-	+	+	+	-
Class III mal occlusion	-	-	-	+	-	+	-	-
Class II mal occlusion	+	+	-	-	+	-	-	+

(+) Presence, (-) Absence.

Table (4) Radiographical findings of the patients

Radiographical findings	NO.1	NO.2	NO.3	NO.4	NO.5	NO.6	NO.7	NO.8
Prominent antgonial notch	+	+	+	-	+	-	+	+
Short ramus	+	+	+	-	+	-	+	+
Hypoplasia of mandible	-	+	+	-	-	+	-	+
Hypoplasia of zygomatic bone	+	+	+	+	+	+	+	+
Hypoplasia of maxillary sinus	+	+	+	-	+	+	+	+

(+) Presence, (-) Absence

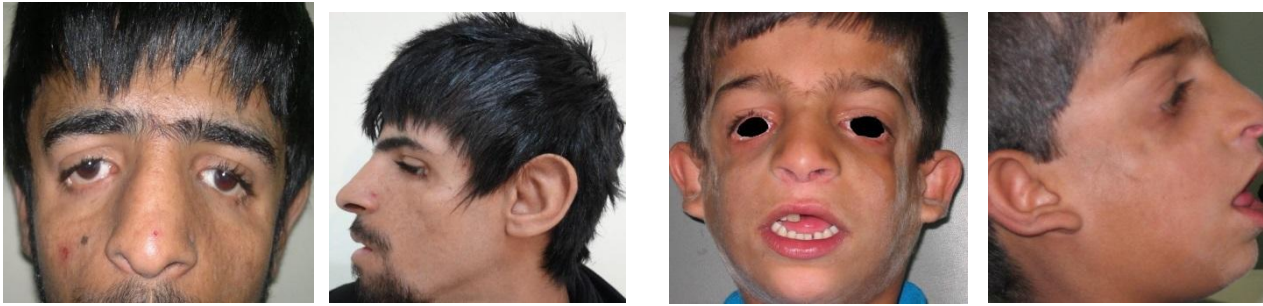

Fig 1: Frontal and lateral views of 2 patients showing the antimongoloid slants of the palpebral fissures, zygomatic hypoplasia, coloboma of the lower lid, macrostomia, and absence of lower eyelashes.

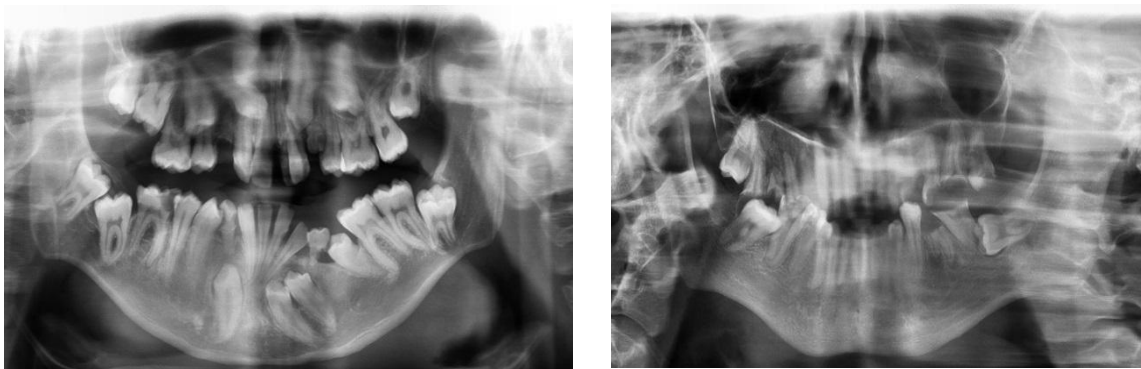


Fig.2:Orthopantographs showed multiple impactions of the teeth with disturbed dental occlusion

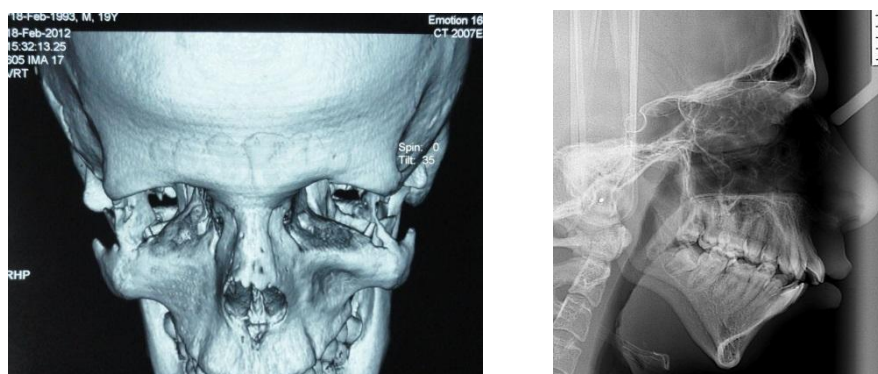


Fig.3:Radiographical findings demonstrates hypoplasia of the zygoma and short ramus of the mandible

Discussion

An understanding the pathogenesis of craniofacial anomalies will assess in their prevention and treatment specially when discovered early. Most of craniofacial tissues were generated form neural crest cell which originated from the neuroectoderm in the period of embryogenesis. These cells undergo migration, proliferation and differentiation forming facial bones. Hence the craniofacial syndromes results owing to the

defect in neural crest cell that occur during different stages of morphogenesis which explain the underlying causes of TCS⁽⁵⁾.

Many orofacial anomalies associated with TCS are disturbs the function of the oral cavity in addition to cause esthetic problems of the patients. . Franceschetti and Klein revised the previous data in literature and defined the typical features of the TCS as follows: 1) Antimongoloid slanting of palpebral fissures with notch or coloboma of the outer third of the lower eye lid, and occasional absence or paucity of the lashes. 2) Facial bones hypoplasia mainly the zygoma and mandible. 3) Ear deformity. 4) High palate ,macrostomia, and disturbed occlusion . 5) Atypical tongue-shaped hair growth covering the pre-auricular region. 6) Associated anomalies, like obliteration of the naso-frontal angle, pits or clefts between the angle of the mouth and ear, and skeletal malformations⁽⁴⁾

Later on Axelsson et al (1963) named the following anomalies as “obligatory” findings:

1) Palpebral fissures antimongoloidslanting. 2) Lower lidcoloboma of the outer third or lashesdeficient, or both. 3) Malar bones hypoplasia 4) Mandible Hypoplasia ⁽¹⁰⁾.According to these criteria all patients 100% in this study had expressed the minimal obligatory criteria, and more than the halfshowed all the obligatory features.

Franceschetti and Klein described five clinical forms of TCS:1) complete form which includes all known features, 2) incomplete form which have variable less severe abnormalities of ear, eye, zygoma and mandible, 3) abortive form have zygomatic hypoplasia and lower lid pseudocoloboma , 4) unilateral form which affects one side of the face and 5) atypical form associated with other anomalies not usually part of typical TCS.Accordingly patients of this study were incomplete and abortive forms of syndrome, characterized by bilateral and symmetrical malformations ⁽⁴⁾.

There are wide variable clinical manifestations of TSC so it's mandatory to confirm the diagnosis of the syndrome when two obligatory features are presents includeshypoplasia of zygomatic bones and downward slanting of palpebral fissures. In this study all patients had the above mentioned obligatory clinical features with variable facial manifestations of the syndrome. This highpoint the importance of intra oral and radiographical examinations to correlates their findings with the clinical one. Imaging technology plays an important role in identification of these cases with minimum manifestation of the syndrome. On the other hand genetic counseling is recommended for the affected individual or parents for screening of the syndrome and possibility of transmission to next generation.

In the present study only 2 patients had family history of the syndrome. This is due the fact that about 60% of TCS patients have negative family history and the syndrome developed as a consequence of *de novo* mutation while 40 % of the patients have positive history owing to familial mutation alteration in TCOF1 gene⁽⁵⁾.

Early detection of TCSpermits to plan the treatment strategy efficiently which recover the function and esthetic problems of the patient or may prevent the development of the syndrome.Genetic studies showed that inhibition of p53 function can suppress the program of neuroepithelial apoptosis with restoration of the neural crest celland prevent craniofacial anomalies associated with TCS ⁽¹¹⁾.

Generally the treatment methods for TCS patient can be designed according to the age of affected individual. In the early life management of air way, ear and speech problem had the utmost priorities in treatment plan the patients. Under development of the facial bone particularly the retruded or micrognathia of the mandible will reduce the retropharyngeal space and compress the airway⁽¹²⁾.

Although no patient in this study had airway problem TCS may cause severe respiratory distress and sleep apnea. Different procedures were used to manage the air way complications which include adhesion of the tongue to the lower lip, surgical advancement of the mandible or tracheostomy in severe cases^(13,14).

Two of patients in this study used hearing aid device to overcome deafness associated with TCS. For such complications early intervention is need to preserve the learning integrity of speech and communication skill which may be affected if the problem is not resolved. Normally hearing examination needs to be done at the first year of life whereas ear reconstruction can be done at 5-10 years of age. Many surgical techniques can be applied now a day for correction of the external ear using autogenous tissues with a good outcome^(15,16). Despite the wide variable deformities in the craniofacial region in the TCS a multidisciplinary team can achieve a good outcome in treatment of this patient. Different specialties can contribute to this team include maxillofacial surgery, plastic surgery, orthodontics, general dentistry, otolaryngology and psychiatry. It is important to consider the intra oral abnormalities during the assessment and planning of the treatment methods.

All patients in this report showed dental problems beside to deformities of the maxilla and mandible bones. Dental findings include malocclusion, anterior open bite and multiple impactions. In addition to zygomatic hypoplasia many patients had micrognathia of the mandible, short ramus of the mandible, maxillary sinus hypoplasia. Majority of dental problems can be treated effectively during the early childhood and adolescent area based on advances in imaging technology like cone beam computed tomography, material and surgical procedures. This will improve the quality of the life of the patient and makes further treatment steps easier and less complicated.

In this field osteogenesis distraction of the mandible consider an effective treatment modality in case of airway problem or to restore the shape of bone as many patients have micrognathia. Different distractors can be used for several times to improve both esthetic and function^(13,14). Moreover the use of myofunctional appliances with orthodontic treatment will overcome the growth problem of jaws bone and make good alignment of the teeth. The principles of actions of these appliances are to modify and stimulate facial bone growth as the TCS is congenital disorder and there were no further deformities after the birth. In the present study only one patient had cleft palate however other studies showed about 35% of TCS patient had cleft palate and 40% had velopharyngeal incompetence⁽¹⁷⁾.

On the other hand the oral hygiene and dental care therapy should be not overlooked in the patients due the complexity of the syndrome which exaggerated by malocclusion and mal positioned teeth. Adequate dental treatment will improve the quality of the life of the patients and decrease their sufferance.

In conclusion TCS had variable manifestation need early detection and management since patient birth. Proper treatment plan by multidisciplinary team utilizing modern methods will achieve good out come and improve the quality of the life of patients.

References

- 1- Scully C, Langdon J, Evans J. Marathon of eponyms: 20 Treacher Collins syndrome. Oral Dis 2011;17 (6):619–620
- 2- Poswillo D. The pathogenesis of the Treacher Collins syndrome(mandibulofacial dysostosis). Br J Oral Surg 1975; 13 (1):1–26.
- 3- Christopher C, Derek M. Treacher Collins Syndrome . Seminars in Plastic Surgery 2012; 26 (2): 83-90.
- 4- Franceschetti A, Klein D. Mandibulo-facial dysostosis: new hereditary syndrome. Acta Ophthal 1949; 27:143-224.
- 5- Dixon J, Ellis I, Bottani A, Temple K, Dixon M. Identification of mutations in TCOF1: use of molecular analysis in the pre- and postnatal diagnosis of Treacher Collins syndrome. Am J Med Genet A 2004; 127:244-248.
- 6- Marszalek B, Wojcicki P, Kobus K, Trzeciak W. Clinical features, treatment and genetic background of Treacher Collins syndrome. J Appl Genet 2002; 43:223-233.

- 7- Behrents R, McNamara J, Avery J. Prenatal mandibulofacial dysostosis (Treacher Collins syndrome). Cleft Palate J 1977; 14:13.
- 8- Gisele da Silva ,Beatriz Costa, MarciGomide,Prevalence of dental anomalies, ectopic eruption and associated oral malformations in subjects with Treacher Collins syndrome. OralSurg Oral Med Oral Pathol Oral RadiolEndod2006; 101 (5):588-592.
- 9- Marina H, CristianedaSilveira, Carla M , Marcelo Cavalcanti .Clinical and imaging correlations of Treacher Collins syndrome: Report of two cases.OralSurg Oral Med Oral Pathol Oral RadiolEndod 2007 ;103 (6) :836-842
- 10- Axelssona A, Brolina I, Engströma H, Lidéna G. DysostosisMandibulo-Facialis. The Journal of Laryngology & Otology1963; 77 (7):575- 592.
- 11- Jones N, Lynn M, Gaudenz K, Sakai D, Aoto K, Rey J, Glynn E, Ellington L, Du C, Dixon J, Dixon M, Trainor P. Prevention of the neurocristopathyTreacher Collins syndrome throughinhibition of p53 function. Nat Med. 2008; 14:125–133.
- 12- Jeffrey C, Paul S, Bernard J. Treacher Collins syndrome: comprehensive evaluationand treatment.Oral Maxillofacial SurgClin N Am 2004;16 :503 – 523.
- 13- Miloro M. Mandibular distraction osteogenesis for pediatric airway management. J Oral MaxillofacSurg 2010; 68(7):1512–1523.
- 14- Steinbacher D, Kaban L, Troulis M. Mandibular advancementby distraction osteogenesis for tracheostomy-dependent childrenwith severe micrognathia. J Oral MaxillofacSurg 2005;63(8):1072-1079.
- 15- Tanzer R. Total reconstruction of the auricle. The evolution of aplan of treatment. PlastReconstrSurg 1971;47(6):523–533.
- 16- Brent B. Microtia repair with rib cartilage grafts: a review ofpersonal experience with 1000 cases. ClinPlastSurg 2002;29(2):257–271.
- 17- Bresnick S, Walker J, Clarke-Sheehan N, Reinisch J. Increased fistula risk following palatoplasty in Treacher Collins syndrome.Cleft Palate Craniofac J 2003;40:280-283.