



Variation in the Origin of Left Hepatic Artery in North East Population

Authors

Dr Bandita Medhi¹, Dr Yogesh Tatwade²

¹Asst. Prof., Index Medical College Hospital & Research Centre, Indore

Consultant Plastic Surgery, Bombay Hospital

Correspondence Author

Dr Yogesh Tatwade

Abstract

The Hepatic arterial anatomy is a gateway to successful hepatobiliary surgeries. It represents one of the many “lessons for general surgeon” as liver transplantation has become a novel life saving surgical procedure. Pre-operative arterial imaging is of utmost importance to plan hepatobiliary surgeries. The Common Hepatic artery bifurcates into left & right hepatic arteries on reaching porta hepatis. These are end arteries & supply right & left halves of liver respectively. The Left Hepatic artery runs vertically towards the umbilical fissure & supplies I, II & III segments of the liver. It usually gives middle hepatic artery that supplies segment IVa & IVb. Abberant left hepatic artery may arise from left gastric, left gastro duodenal, right hepatic, celiac trunk, splenic or superior mesenteric artery (Williams et al, 1996). The Origin of left hepatic artery was studied in 50 cases by dissection method. After dissecting, the branching pattern of the common hepatic artery was noted and the arteries were painted using red Fevicryl paint & photographs were taken. Each photograph was given specimen number. In the study it was found that Left Hepatic artery originated from left gastric Artery in 8 cases, from Hepatic Artery proper in 35 cases and from Common Hepatic artery in 7 cases. The gastrohepatic ligament which connects the lesser curvature of stomach to liver usually contains both Right & Left gastric arteries. Thus, in cases where left hepatic artery is originating from left gastric artery, one must remember this variation while dividing the ligament during surgical procedures involving gastro esophageal junction.

Introduction

The knowledge of anatomical variation of the hepatic artery and its branches are important in planning and performing of hepatobiliary surgeries. Hepatic arterial anatomy has been studied for many centuries, receiving attention from great scholars like Aristotle & Galen. However, only in 18th century with Jacques Benigne Winslow & Albert Haller, who were considered Father of Modern Angiology, its blood irrigation was set

correctly and from that many anatomical variations were studied from time to time^{1,2}.

In this study we are taking the variation of Left Hepatic Artery in consideration as it is one of the most important branches of Common Hepatic Artery. The Common Hepatic Artery bifurcates into right & left hepatic arteries on reaching the Porta Hepatis. These are end arteries and supply the right & left half of liver respectively. The Left Hepatic Artery then runs vertically in the

umbilical fissure and supplies I, II & III segments of the liver. It usually gives middle hepatic artery that supplies IV a and IV b segments. According to various literatures aberrant left hepatic artery may arise from left gastric / right hepatic/ splenic artery/ superior mesenteric / gastro duodenal/ coeliac or from abdominal aorta (Hollinshed & Rosse, 1985) A new emphasize is given to this as orthotopic liver transplantation has come up as a life saving procedure^{3,4,5}.

Given the high incidence of variation in hepatic arterial system & its influence on procedures involving this region, it is critical that it be thoroughly studied. Thus a significant number of complications can be avoided when the recognition of possible anatomical variations are kept in mind by surgeons and interventional radiologists⁶.

The objective of the study was to dissect human cadavers and to find out the variation of origin of Left Hepatic Artery and compare the results with available literature, thus, contributing further to the knowledge of the students and professionals working in this area.

Materials & Method

The origin of Left Hepatic Artery was studied in 50 cadavers by Dissection Method. The dissection

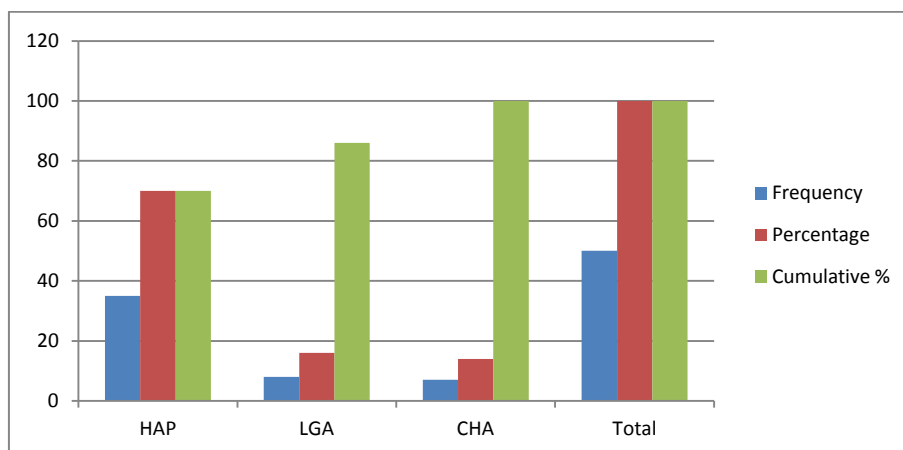
was done in 50 embalmed cadavers, both male and females, over a time span of 2 years i.e. June 2009 to May 2011 in Department of Anatomy in Gauhati Medical College, Guwahati. After meticulously dissecting the branches of Common Hepatic Artery they were indentified. Of the branches, the Left Hepatic Artery was traced to see its origin & then it was painted using red fevicryl paint & necessary photographs were taken. The results obtained were statistically analyzed by using contingency table analysis & Chi Square test.

Results & Observation

The Left Hepatic Artery was seen arising from Hepatic Artery Proper in 35 cases, from Left Gastric artery in 08 cases & from Common Hepatic Artery in 07 cases. During dissection the left hepatic artery was seen originating from the left gastric artery & was found between the 02 layers of gastro hepatic ligament. Chi Square value of 0.004 was found to be highly significant. Indicating that maximum no. of cases were observed in hepatic artery proper (35) followed by left gastric artery (08) & least number in common hepatic artery (07). The findings are tabulated below:

	Site of Origin	Frequency	Percentage	Cumulative %
Left Hepatic Artery	Hapetic Aetery Proper	35	70	70
	Left Gastric Artery	08	16	86
	Common Hepatic Artery	07	14	100
	Total	50	100	100

Bar Diagram



Discussion

Hepatobiliary variations are of great concern to surgeons and interventional radiologist. The Common Hepatic Artery usually divides into right & left hepatic arteries at the porta hepatis to supply the right & left halves of the liver respectively. Previous studies have shown that aberrant left hepatic artery may arise from left gastric, coeliac trunk directly, right hepatic, splenic, superior mesenteric, gastroduodenal or directly from abdominal aorta⁷.

In present study it was observed the Left Hepatic Artery originated from Hepatic Artery Proper in 70% cases, Michels (1955) observed the same in 85 % cases. Left Hepatic Artery began from Common Hepatic Artery in 14% cases in this study & Jones & Hardy (2001) concluded in their study that 81 % cases of Left Hepatic Artery began from Common Hepatic Artery^{5,6,8,9}.

The origin of Left Hepatic Artery from Left Gastric Artery in the present study was found to be 16 % which almost tallies with the findings of Michel (11%) & Jones & Hardy (15%). Their study did not include the origin of Left Hepatic Artery from Hepatic Artery Proper as it considered the normal anatomy. The significance of aberrant left hepatic artery arising from left gastric artery at curative gastrectomy for gastric cancer has been studied extensively by Shinohara et al (2007). Similarly, the significance of the anomalous origin of left hepatic artery from left gastric artery in operations upon the stomach & esophagus have been studied by Frieson SR (1957)^{10,11}.

In the present study we have also found that left hepatic artery may originate from common hepatic artery (14%). Sultana et al found that the origin of the right & left hepatic artery from Hepatic Artery Proper was 75% and in 25% cases it was found to arise from other sources. The right hepatic artery was found to rise from Common Hepatic Artery in 18% & 7% from superior mesenteric Artery, but in case of left hepatic artery remaining 15% was originating from

Common Hepatic Artery which almost correlates with the present study.

Futura et al reported in their study the origin of Left Hepatic Artery from Hepatic Artery Proper (71.8%), Common Hepatic Artery (16.4%), coeliac trunk (10.9%) & the splenic artery (0.9%). These findings of the variant origin of left hepatic artery are almost similar to the findings in the present study. Hiatt JR et al studied anatomy of hepatic arteries in 1000 cases & classified the pattern of hepatic artery branching into six types. In our study during dissection we have found Type I (Normal), Type II (Origin of left hepatic artery from left gastric artery) according to Hiatt's classification^{9,12}.

Conclusion

The anatomical knowledge of aberrant origin of left hepatic artery is important factor to achieve success in hepatobiliary surgeries, liver transplantation, gastrectomies, hiatal surgeries for gastro esophageal reflux, bariatric surgeries and selective arterial chemotherapy for liver cancer. Left hepatic artery arising from left gastric artery was observed in 16% cases. This branch lies between the two layers of lesser momentum and therefore surgeon must be cautious while dividing the ligament to reach the gastro esophageal junction. Therefore, we consider the study and research on the variation of origin of left hepatic artery a real need as it contributes unequivocally to the practice of medicine and in particular to surgery with which it has a fundamental relationship.

References

1. T Shinohara, S Ohyama, T Muto, K Yanaga, T Yamaguchi (2007), The significance of aberrant left hepatic artery arising from left gastric artery at curative gastrectomy for gastric cancer; *European Journal of Surgical Oncology* 33 (8), 967-971.
2. James B. Naidichi, Thomas P Naidichi, Seymour Spraygreen, Roger A Hyman,

- Rochelle M Pudlowski, Harry L Stein, The origin of left gastric artery (1978), Radiology Vol. 126: Issue 3; 623-626.
3. PJ Klingler, MH Sulig, NR Floch, SA Branton, MC Freud, N Katada, RA Hinder; Abberant left hepatic artery in laproscopic antireflux procedures(2004); Surgical Endoscopy & other Interventional techniques 18 (5); 807-811.
 4. SR Friesen; The significance of the anomalous origin of left hepatic artery from left gastric artery in operation upon the stomach & esophagus(1957); The American Surgeons 23 (12); 1103.
 5. Jones RM, Hardy KJ, The Hepatic artery: A reminder of surgical anatomy(2001); Journal of the Royal College of Surgeons of Edinburgh ; vol: 46 issue 3, 168-170
 6. Michels NA; Blood supply and anatomy of the upper abdominal organs(1955), USA: JB Lippincott company, 32-73.
 7. Hollinshead H, Rosse C (1985) text book of anatomy 4th edition Philadelphia: Harper and Row: 324-640.
 8. R Shakuntala Pai, A Shahin Hunnarge Mamata Srinivasan; Accessory left hepatic artery arising from common hepatic artery (2008); Indian Journal of Surgery; 70(2), 80-82.
 9. Futora GI ; Variation of hepatic & cystic arteries(2001). Ethiop Med J 39(2):133-142
 10. Sultana ZR, Khalil M, Rahman H, Sultana SZ, Mannan S, et al (2009) The origin of right & left hepatic arteries supplying the liver & gallbladder; Pub Med 18(1): S29 - S33.
 11. Strandring S; Gray's Anatomy; Liver, The anatomical basis of clinical practice, 40th edition Edinbrough: Elsewier Churchill Livingstone,(2008) p-2144-2145.
 12. Hiatt JR et al; Surgical Anatomy of Hepatic Artery in 1000 cases; Annals of Surgery (1994); 220 (1): 50-52.