



Multidetector Computed Tomography in Evaluation of Lung Masses: Study from South India

Authors

Dr Anitha Nadaraj¹, Dr Mini MV², Dr Akhil R Nambiar³, Dr Suny Thomas⁴

¹Asst Professor, Department of Radiology, Government Medical College, Thrissur 680696

²Professor, Department of Radiology, Government Medical College, Thrissur 680696

³Resident, Department of Radiology, Government Medical College, Thrissur 680696

⁴Professor and Head of Department of Radiology, Government Medical College, Thrissur 680696

Corresponding Author

Dr Akhil R Nambiar

Anjali, Chirakkal, Kannur 670011

Abstract

Background: *Bronchogenic carcinoma is the leading cause of cancer-related death worldwide in men and second most-common in women after breast cancer. Patients with bronchogenic carcinoma have poor prognosis with an overall survival rate of 10-15%. The early detection and accurate staging of bronchogenic cancer is crucial in planning the optimal treatment modalities and further management. Radiological imaging plays a critical role in the initial detection and diagnosis of lung cancer. Multi Detector computed tomography (MDCT) is the standard modality of choice for evaluating the lung cancer because of its better spatial resolution. CT has a role in identifying the lung nodules and characterizing them as benign or malignant.*

Objectives: *The study aims to assess the accuracy of Multi detector computed tomography in diagnosis and staging of Bronchogenic carcinoma. The study also intends to identify the various imaging characteristics types of bronchogenic carcinoma by MDCT.*

Methodology: *This study was a descriptive study conducted on 80 subjects with clinically or radiologically suspicious bronchogenic carcinoma who were referred to department of radio diagnosis, Govt Medical college, Thrissur for undergoing contrast enhanced CT over a period of one year, and were selected based on inclusion and exclusion criteria. Pre and post contrast CT scans were performed. Lung lesions were analysed based on various variables and staging and provisional diagnosis were made and then correlated with histopathology. The data was managed using Microsoft Excel 2016 and statistical analysis was done with IBM SPSS Statistics v25. The sensitivity, specificity, positive predictive value, negative predictive value and accuracy of each characteristic as well as the combined values in comparison to histopathological findings were obtained.*

Results: *Majority of the patients belonged to 60 – 70 years age group (47.5%) with male predominance (77.5%). About 66.8 % patients had history of smoking. Cough and dyspnea were the commonest symptoms. Most common radiological finding was central hilar mass lesion (57.5 %) followed by peripheral lesion in 42.5 %. Squamous cell carcinoma was the most common histopathological type*

(46.3%), followed by adenocarcinoma (22.5%) then small cell carcinoma (12.5%). The most common lobe affected by bronchogenic carcinoma was right upper lobe. The most common site of distant metastasis was adrenal gland (42.6%) followed by pleura (35.3%) and then liver (29.4%). Majority of the patients (69.1%) presented with TNM stage IV.

Conclusions: Overall, CT had a sensitivity of 95.7% and specificity of 81.8%, positive predictive value of 97.1% and negative predictive value of 75%. Multi detector computed tomography has high positive predictive value suggestive of great diagnostic accuracy in the evaluation of bronchogenic carcinoma. MDCT is a useful tool in the staging of Bronchogenic Carcinoma.

Keywords: Multidetector Computed Tomography (MDCT), Bronchogenic Carcinoma, Histopathology.

Background And Introduction

Bronchogenic carcinoma is the leading cause of cancer-related death worldwide in men and second most-common in women after breast cancer. Its incidence is raising at alarming rates at developing countries. Although the underlying aetiology for this malignancy is multifactorial, approximately 85% of bronchogenic carcinoma deaths are attributable to cigarette smoking (1). Multi Detector computed tomography (MDCT) is the standard modality of choice for evaluating the lung cancer because of its better spatial resolution (2) MDCT provides precise characterisation of the size, contour, extent and tissue composition of the suspicious lesion. It identifies small nodules not visible by radiography. It also has role in characterizing them as benign or malignant. MDCT accurately stages the tumours because of the superior multiplanar reformatted images. Staging of lung cancer plays a vital role in deciding the treatment and helps in accessing the prognosis. The present study is aimed at assessing the diagnostic accuracy of MDCT in the evaluation and staging of bronchogenic carcinoma and at evaluating the imaging characteristics of bronchogenic carcinoma with histopathological correlation.

Objective

1. To document the imaging characteristics of bronchogenic carcinoma using multidetector computed tomography in adult patients referred for evaluation of lung masses in a tertiary care centre in South India.
2. To calculate the diagnostic efficiency of MDCT in detection of malignancy in

patients referred for evaluation of lung masses, taking Histopathology as gold standard

Methodology

It was conducted as a cross sectional analytical study over a period of one year in the department of radio diagnosis.

Patients included in the study were adults with clinically or radiologically suspected bronchogenic carcinoma who were referred to the department of radio diagnosis, in whom histopathology correlation was available.

Previously diagnosed cases of carcinoma lung were excluded from the study. The examinations were performed using Siemens Somatom16 slice CT scanner with 5mm section thickness, and reformed to 1.5mm section thickness. Scanning images included pre and post administration of contrast medium in all patients. Sections were taken from the level of lung apices to up to adrenals.

Patients were followed up with histopathological examination of the specimen obtained from FNAC/ biopsy of the lesion and results were compared with CT findings. The data was managed using Microsoft Excel 2016 and statistical analysis was done with IBM SPSS Statistics v25. The sensitivity, specificity, positive predictive value, negative predictive value and accuracy of each characteristic as well as the combined values in comparison to histopathological findings were obtained.

Observations and Results

A total of 80 subjects were included in the study, ranging in age group from 40 to 75.

In this study, 5 (6.3%) participants were in the age group of 40-50 years, 14 (17.5%) were in the age group of 51-60 years, 38 (47.5%) were in the age group of 61-70 years and 23 (28.8%) were in the age group of more than 71-75 years.

In the study, 62 (77.5%) participants were male and 18 (22.5%) were females.

Of the 80 patients, 55 (68.8%) gave a history of smoking.

The most common presenting symptoms were cough in 75 participants (93.8%) followed by dyspnea in 70 (87.5%) participants.

All patients had masses detected in X Ray. The various findings have been elaborated in tables that follows.

Table 1 gives the distribution of site of mass lesion, most common being central in 57.5% of cases

Table 1: Distribution of site of lung mass in CT

Site of Lesion	Frequency (n=80)	Percentage
Right Upper Lobe	33	41.3
Right Middle	13	16.3
Right Lower	16	20.0
Left Upper	18	22.5
Left Lower	17	21.3
Central	46	57.5
Peripheral	34	42.5

Most of the lesions were more than 4 cm, highest number of cases being more than 7 cm (30%)

Table 2: Distribution of size of lung mass in CT

Size of lesion	Frequency	Percentage
1-2 cm	3	3.8
2-3 cm	3	3.8
3-4 cm	12	15.0
4-5 cm	18	22.5
5-7 cm	20	25.0
> 7 cm	24	30.0
Total	80	100.0

The margins were classified into 5 types, the most common being lobulated irregular margins in 42 (52.5%) cases

Table 3: Distribution of contour of lung mass in CT

Contour of Lesion	Frequency	Percentage
Spiculated	28	35.0
Lobulated/irregular	42	52.5
Smooth	4	5.0
Irregular thick-walled cavity	4	5.0
Ill-defined	2	2.5
Total	80	100.0

Different CECT characteristics were studied. In the study, contrast enhancement of the lesion was present in 79 (98.8%) participants. Contrast enhancement was absent in only one case. There were 13 other CT findings looked for in the study as given in table 4..

Table 4: Distribution of other features of lung mass in CT

Other Findings	Frequency (n=80)	Percentage
Calcification	18	22.5
Cavitation	13	16.3
Necrosis	31	38.8
Bronchial cut off	37	46.3
Satellite lesions	24	30.0
Pleural thickening	35	43.8
Collapse	37	46.3
Consolidation	17	21.3
Interstitial thickening	30	37.5
Chest wall infiltration	11	13.8
Mediastinal infiltration	40	50.0
Vocal cord palsy	2	2.5
Diaphragmatic palsy	3	3.8

Enlarged lymph nodes were documented at peri bronchial, mediastinal, hilar and distant sites (supraclavicular and scalene). The distribution is as given in table 5.

Table 5: Distribution of Mediastinal and Hilar Lymphadenopathy in CT

Nodes	Frequency (n=80)	Percentage
Peri bronchial	23	28.8
Mediastinal		
Ipsilateral	58	72.5
Contralateral	17	21.3
Subcarinal	54	67.5
Hilar		
Ipsilateral	37	46.3
Contralateral	8	10.0
Supraclavicular	14	17.5
Scalene	0	0.0

Table 6: Distribution of presumed metastatic lesions in CT

Metastases	Frequency (n=68)	Percentage
Opposite lung	33	48.5
Liver	20	29.4
Bone	16	23.5
Adrenal	29	42.6
Pleural nodules	24	35.3
Pleural effusion	23	33.8
Extra thoracic nodes	12	17.6
Others	6	8.8

Table 6 gives the distribution of enhancing masses presumed to be metastasis.

In the study, metastasis to the opposite lung was noted in 33 (48.5%) participants. Adrenal gland was the most common site of distant metastasis, in 29 (42.6%), followed by liver in 20 (29.4%), then bone in 16 (23.5%). Metastasis to extra thoracic nodes noted in 12 (17.6%) and 6 (8.8%) of participants had metastases to other sites like brain, kidney. Pleural nodules were seen in 24 (35.3%) and pleural effusion in 23 (33.8%),

Table 7: Distribution of final diagnosis from CT

Impression from CT	Frequency	Percentage
Malignant	68	85.0
Benign	5	6.3
Infection	7	8.8
Total	80	100.0

In the study of 80 participants, from CT evaluation, a final impression were made. As described in table 7, 68 (85.0%) lesions were diagnosed as malignant, 5 (6.3%) were benign and 7 (8.8%) belonged to infective etiology based on impression from Computed Tomography evaluation.

Table 8: Of the 68 with impression of Malignancy in CT, the staging were given as follows:

Tumour (T)	Frequency	Percentage
T1a	1	1.4
T1b	2	2.9
T2a	3	4.4
T2b	4	5.8
T3	11	16.1
T4	47	69.1
Total	68	100.0

Based on CT based approach, Tumor Node Metastasis (TNM) staging was done, which is provided in Table 9, 10 and 11 respectively.

Table 9: Distribution of stages of nodes of study participants

Nodes (N)	Frequency	Percentage
N1	3	4.4
N2	42	61.8
N3	23	33.8
Total	68	100.0

Table 10: Distribution of Metastasis of study participants

Metastasis (M)	Frequency	Percentage
M0	11	16.2
M1a	11	16.2
M1b	25	36.8
M1c	21	30.9
Total	68	100.0

On histopathology follow up, the 68 malignant cases were divided into 3 major histo pathological types, viz Squamous cell, adeno, small cell types. The most common type being Squamous cell carcinoma in 48 cases (70.6%).

Table-11: Distribution of types of Malignant lesions based on CT

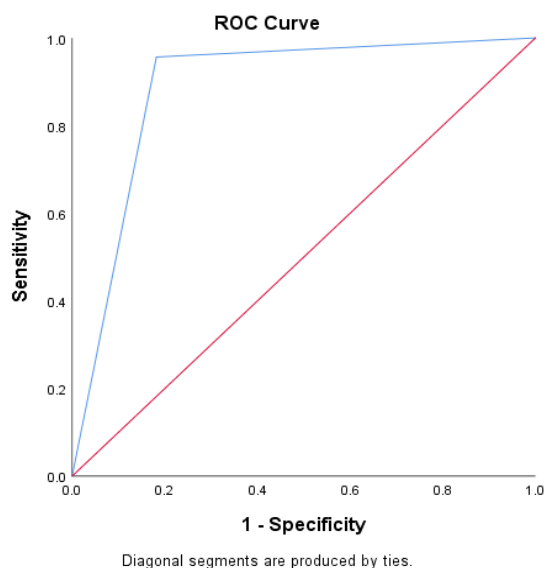
Malignant- types (by CT)	Frequency	Percentage
Squamous cell carcinoma	48	70.6
Adenocarcinoma	18	26.5
Small cell carcinoma	2	2.9
Total	68	100.0

Table 12: Comparison of CT diagnosis with Histological diagnosis of bronchogenic carcinoma.

CT	HPE				P Value
	Malignant		Benign		
	n	%	n	%	
Malignant	66	95.7	2	18.2	1.000
Benign	3	4.3	9	81.8	
Total	69	100.0	11	100.0	

From the above 2X2 table (table 12) , for finding the diagnostic accuracy of CT as a tool for detection of metastasis with Histopathology as gold standard, The sensitivity: $TP / (TP+FN) = 66 / (66+3) = 95.7\%$ Specificity= $TN / (FP+TN) = 9 / (9+2) = 81.8\%$ Positive predictive value to diagnose bronchogenic carcinoma = $TP / TP+FP = 66 / (66+2) = 97.1\%$ The Kappa measurement value of 0.746 revealed that almost perfect agreement between CT diagnosis and Histopathological diagnosis.

Figure-1: ROC curve for CT diagnosis and Histopathological diagn



Discussion

80 cases who had lung masses and had histopathology confirmation were included in the study. Majority were males(77.5%) with maximum patients in the age group of 61-70 years : 38 cases (47.5%).

This is in keeping with usual detection of lung masses in adult males.

There were 14 CT findings looked for in the study. All lung masses showed enhancing areas, except for one which was non enhancing, probably because of near complete necrosis of the lesion. Necrosis , viz non enhancing areas within the solid areas which again may be attributed to benign and malignant causes, was seen in 31 cases.

Definitive evidence of malignancy , viz chest wall infiltration and mediastinal infiltration were noted in 11 and 40 cases respectively. Other features like satellite lesions (24 cases), pleural thickening (35 cases), bronchial cut off (37 cases), vocal cord (2 cases) and diaphragmatic palsy (3 cases) , which directed towards malignancy were also documented in this study. Collapse (37 cases), interstitial thickening (30 cases), consolidation (17 cases), calcification (18 cases) and cavitation (13 cases) were other CT features which were equivocal for benign and malignant. Multiple CT characteristics were elaborated by Purandare et al,⁽³⁾ and that was used in staging of carcinoma lung.

In histopathology, most cases were Squamous cell carcinoma, possibly reflecting smoking incidence in the study population.

In this study, Multi detector computed tomography showed a high positive predictive value (97%) suggestive of great diagnostic accuracy in the evaluation of bronchogenic carcinoma. The Kappa measurement value of 0.746 revealed that almost perfect agreement between CT diagnosis and Histopathological diagnosis

These results were similar to studies conducted by Mohammed et al⁽⁴⁾.

In this study having 68 participants with bronchogenic carcinoma, 1 (1.4%) of the participants had T1a stage, 2 (2.9%) participants

had T1b stage, 3 (4.4%) had T2a stage, 4 (5.8%) had T2b stage, 11 (16.1%) had T3 stage and 49 (72.1%) had T4 stage. Majority of the patients were presented at advanced stages as in stage 4 and stage 3 where surgical treatment is no longer an option. This finding correlated with the study done by Rawat et al⁽⁵⁾, Shetty et al⁽⁶⁾, Prasad R et al⁽⁷⁾, Malik PS et al⁽⁸⁾, and Shah D et al⁽⁹⁾.

Multi detector Computer tomography with precise anatomic details is the imaging modality of choice for evaluating bronchogenic carcinoma. CT provides precise characterization of the size, contour, extent and tissue composition of the suspicious lesion. In the diagnosis of bronchogenic carcinoma, CT is a highly sensitive and specific test. Multi Detector Computed Tomography has a high positive predictive value. Similar results has been reported in previous studies ^(10, 11)

Representative Images.

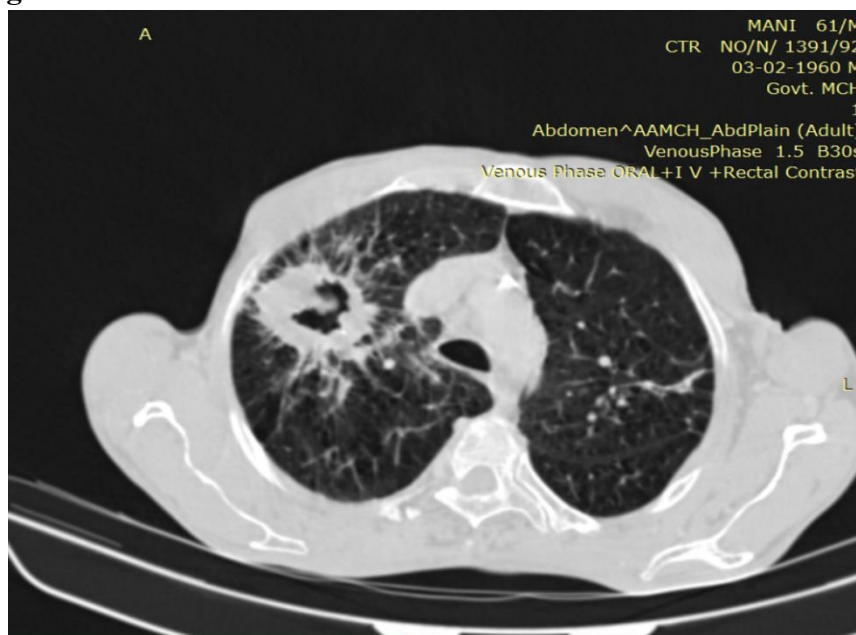


Fig. 2 Axial- CT showing Thick-walled cavity lesion – Squamous Cell Carcinoma

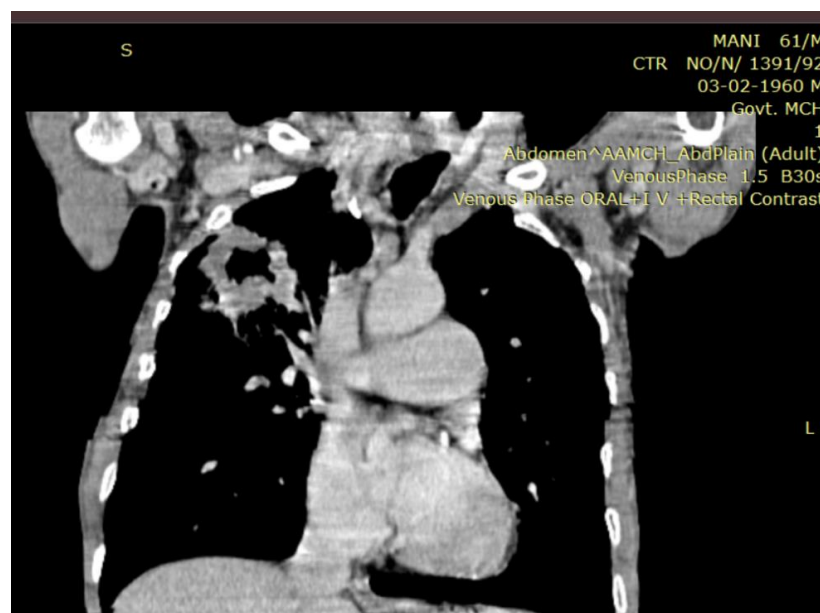


Fig.3: Coronal CECT showing cavity lesion in right upper lobe.

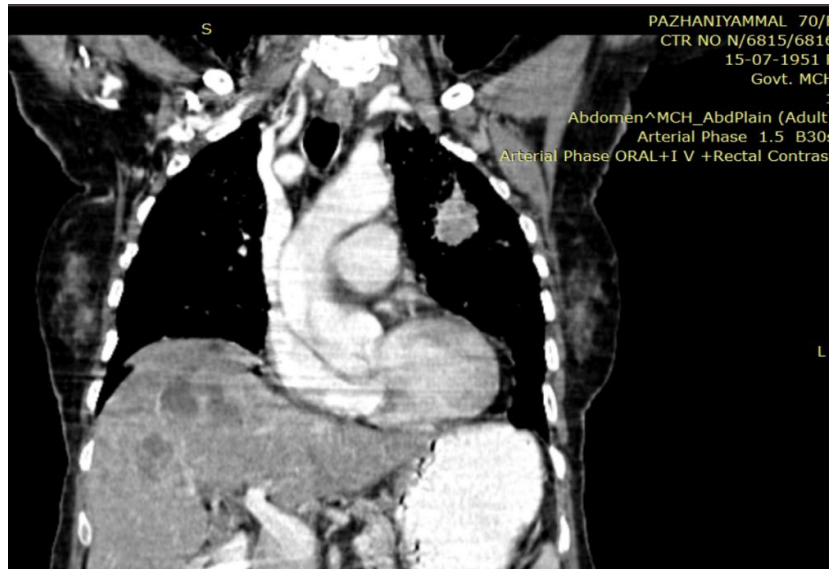


Fig. 4: CECT coronal plane showing left upper lobe mass lesion with liver metastasis. (diagnosed as adenocarcinoma in histopathology)

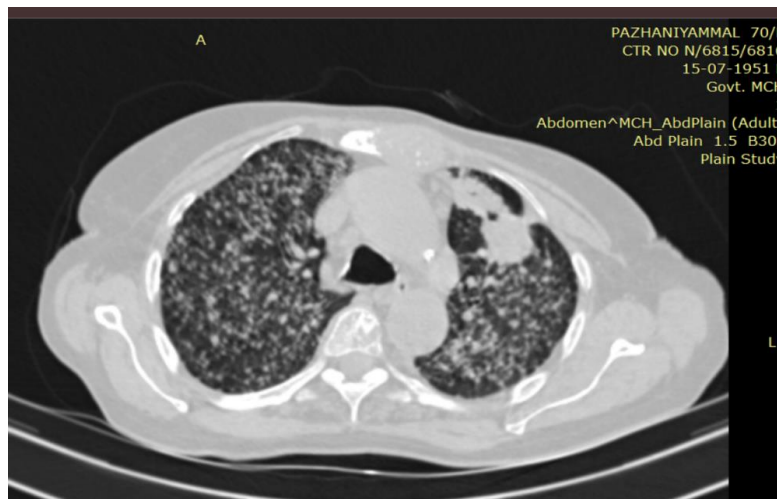


Fig. 5: CT axial plane showing left upper lobe lesion with miliary metastasis & bone metastasis in sternum.

Small cell carcinoma lung

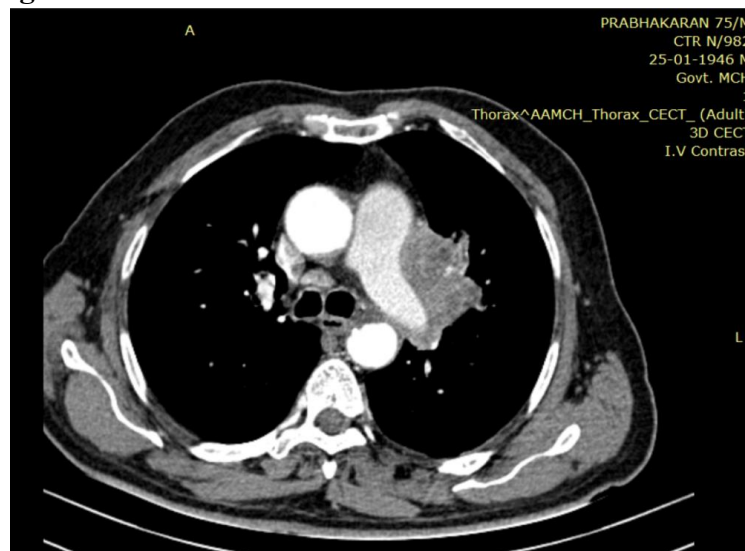


Fig. 6 Axial-CT image showing central mass lesion, diagnosed as small cell carcinoma by histopathology.

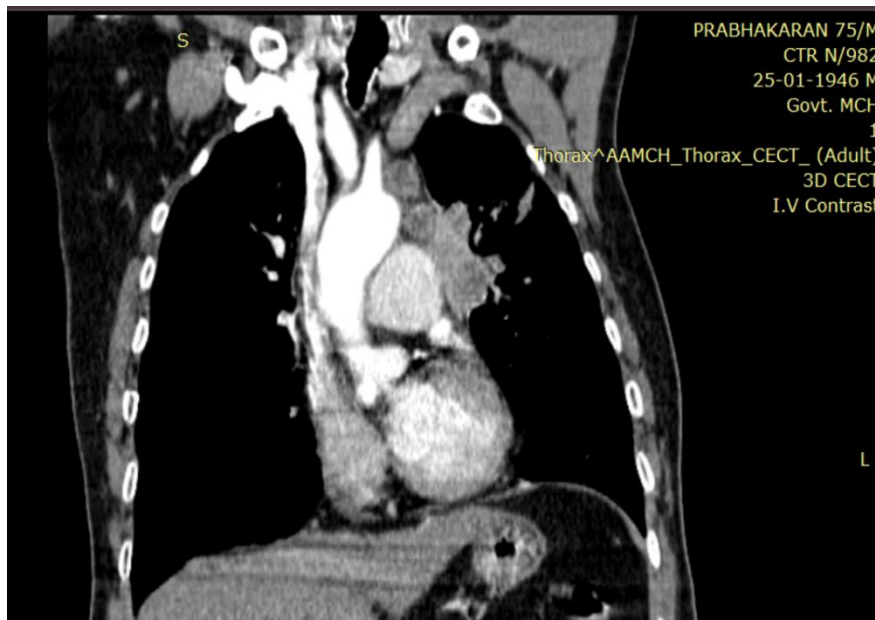


Fig.7: Coronal image of small cell carcinoma with necrotic mediastinal nodes.

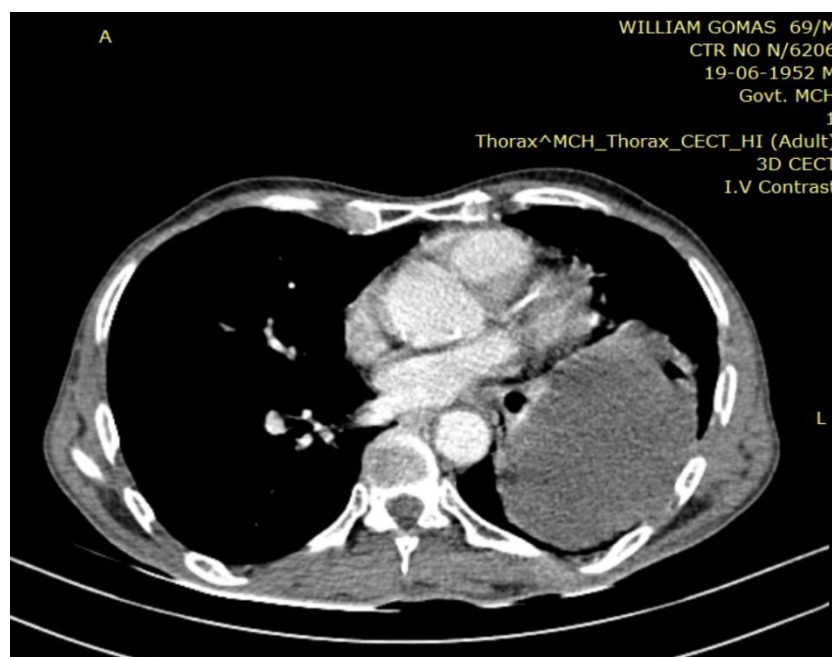


Fig. 8 Axial CT showing large cell carcinoma left lung, by histopathology (Undifferentiated large cell carcinoma)

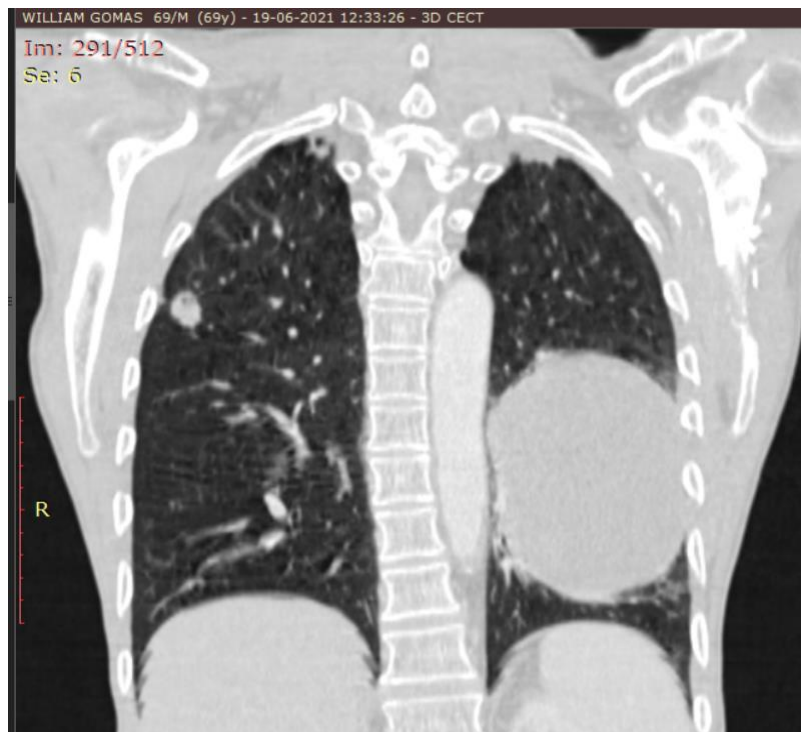


Fig. 9 Coronal CT showing large cell carcinoma with metastasis in opposite lung

Distant metastasis

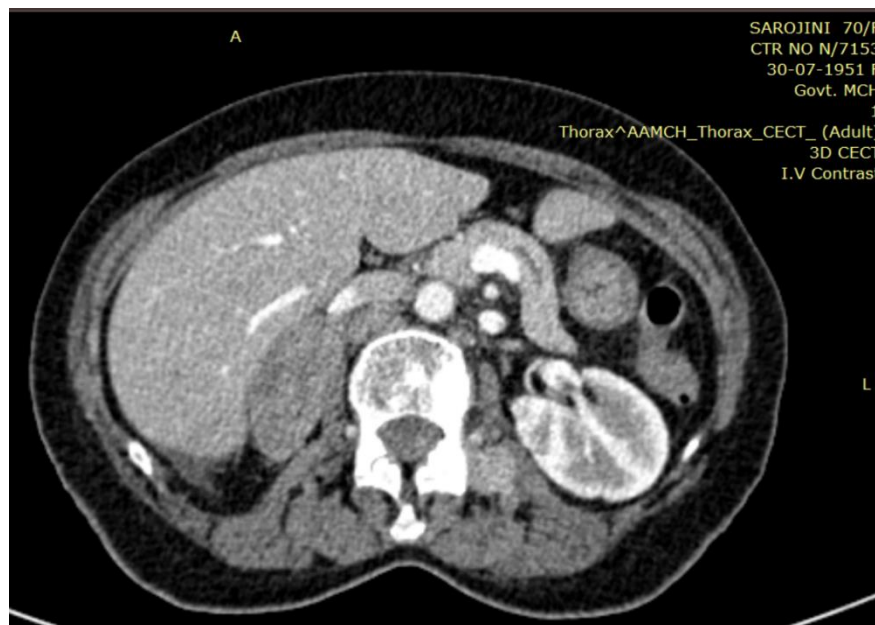


Fig. 10 Axial image showing right adrenal gland metastasis.

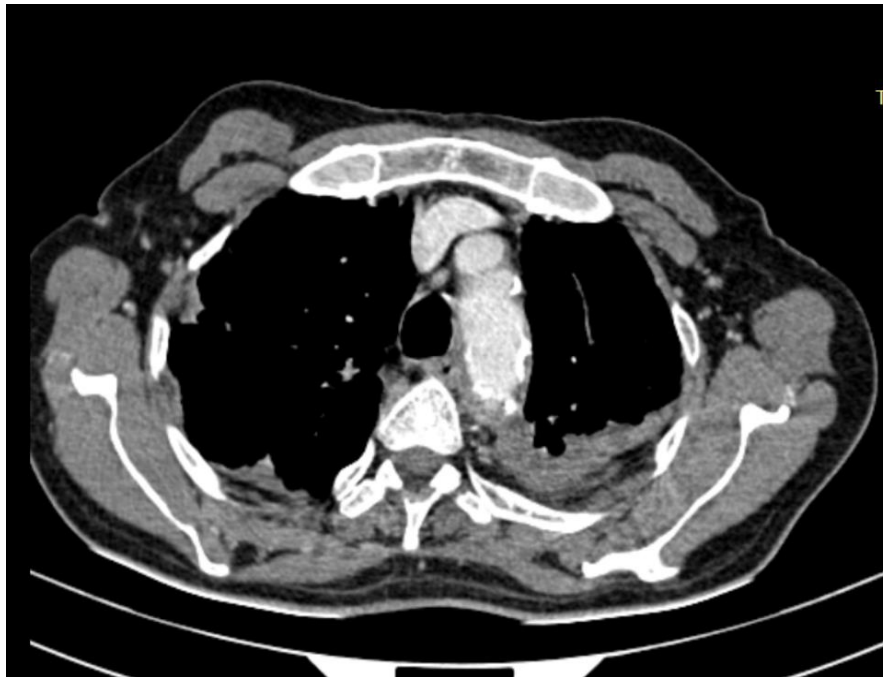

Fig. 11 Axial image with pleural metastasis

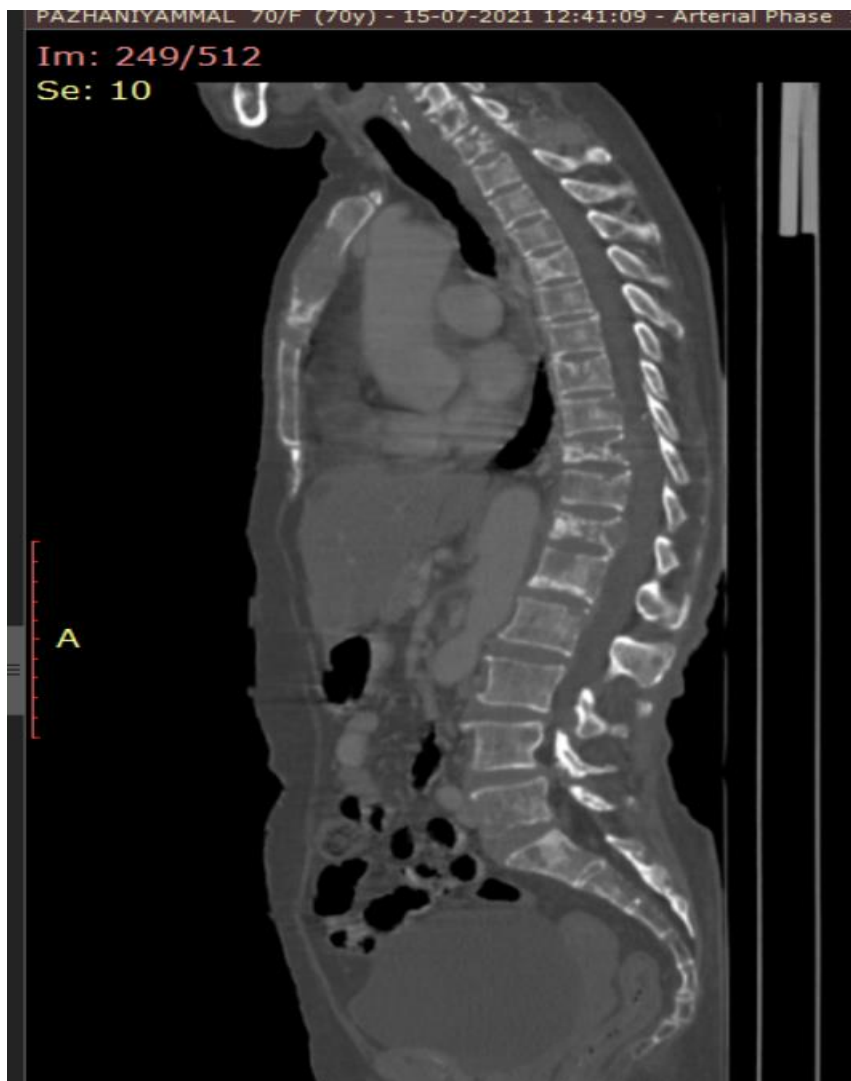

Fig.12 Sagittal image , bone window showing lytic-sclerotic lesions in multiple vertebra

Acknowledgments: Faculty, staff and post graduates of all departments directly or indirectly associated with the study. Also, the patients and bystanders who agreed to use their materials for this study.

Source of supports in form of grants : Nil

Conflict of Interest: None

References

- Alberg AJ, Samet JM. Epidemiology of lung cancer Murray & Nadel's Textbook of Respiratory Medicine. Mason RJ, et al: 5th edition. Saunders Elsevier. 2016:927-39.
- Das CJ, Seith A, Mukhopadhyay S. Thoracic application of multi-detector CT. INDIAN JOURNAL OF CHEST DISEASES AND ALLIED SCIENCES. 2007 Jan 1;49(1):29. <https://pubmed.ncbi.nlm.nih.gov/17256564/>
- Purandare NC, Rangarajan V. Imaging of lung cancer: implications on staging and management. The Indian journal of radiology & imaging. 2015 Apr;25(2):109. doi: 10.4103/0971-3026.155831. PMID: 25969634; PMCID: PMC4419420.
- Mohammad GM. CT guided fine needle aspiration cytology in the diagnosis of thoracic lesions. JIMA. 2001;99(10):1-5.
- Rawat J, Sindhvani G, Gaur D, Dua R, Saini S. Clinico-pathological profile of lung cancer in Uttarakhand. Lung India: official organ of Indian Chest Society. 2009 Jul;26(3):74. <https://pubmed.ncbi.nlm.nih.gov/20442840/>
- Shetty CM, Lakhkar BN, Gangadhar VS, Ramachandran NR. Changing pattern of bronchogenic carcinoma: A statistical variation or a reality?. Indian Journal of radiology and imaging. 2005 Apr;15(02):233-8. <https://doi.org/10.4103/0971-3026.28812q>
- Prasad R, Verma SK. Comparison between young and old patients with bronchogenic carcinoma. Journal of cancer research and therapeutics. 2009 Jan 1;5(1):31. <https://pubmed.ncbi.nlm.nih.gov/19293486/>
- Malik PS, Sharma MC, Mohanti BK, Shukla NK, Deo SV, Mohan A, Kumar G, Raina V. Clinico-pathological profile of lung cancer at AIIMS: A changing paradigm in India. Asian pacific journal of cancer prevention. 2013;14(1):489-94. <https://pubmed.ncbi.nlm.nih.gov/23534779/>
- Shah D, Shastri M, Patel D, Diwanji N, Desai E, Chitara M, Bhatt A. Diagnosis and staging of lung carcinoma with CT scan and its histopathological correlation. International Journal of Research in Medical Sciences. 2017 Jun;5(6):2346. <https://doi.org/10.18203/2320-6012.ijrms20172086>
- Kay FU, Kandathil A, Batra K, Saboo SS, Abbara S, Rajiah P. Revisions to the Tumour, Node, Metastasis staging of lung cancer: Rationale, radiologic findings and clinical implications. World journal of radiology. 2017 Jun 28;9(6):269. <https://pubmed.ncbi.nlm.nih.gov/28717413/>
- Lu F, Li S, Dong B, Zhang S, Lv C, Yang Y. Identification of lung adenocarcinoma mutation status based on histologic subtype: Retrospective analysis of 269 patients. Thoracic Cancer. 2016 Jan;7(1):17-23. <https://pubmed.ncbi.nlm.nih.gov/26816535/>